

## Resveratrol abrogates 5-fluorouracil -induced hepatotoxicity: A preclinical study

Elias Adikwu<sup>1,\*</sup>, Nelson Clemente Ebinyo<sup>1</sup>, Clara Adogbo Ejovwoke<sup>1</sup>

<sup>1</sup>Department of Pharmacology and Toxicology Faculty of Pharmacy, Niger Delta University, Bayelsa State, Nigeria.

### Abstract

The manifestation of acute hepatotoxicity caused by 5-fluorouracil could be characterized by elevations of liver enzymes, hepatic steatosis and fulminant hepatitis. Natural antioxidants have potential as excellent treatment for diseases and drug-induced toxicities. This study assessed the potential of resveratrol (RSV) to abrogate the hepatotoxic effect of 5-FU in rats. Forty adult male albino rats (240±20 g) were randomized and orally supplemented with RSV (10, 20 and 40 mg/kg/day) prior to the administration of 5-FU (20 mg/kg/day) intraperitoneally for 5 days. On day 6, after weighing, the rats were anesthetized, blood samples were collected and sera extracted. Liver tissues were harvested and weighed. Sera and liver tissues were evaluated for biochemical parameters. Liver tissues were assessed for histology. Body weight was significantly ( $P<0.01$ ) decreased whereas liver weight was significantly ( $P<0.01$ ) increased in 5-FU administered rats in relation to control. Serum and liver lactate dehydrogenase, aminotransferases, alkaline phosphatase, gamma-glutamyl transferase, total bilirubin, conjugated bilirubin and malondialdehyde levels were significantly ( $P<0.001$ ) increased in 5FU-administered rats in relation to control. Liver glutathione peroxidase, catalase, glutathione and superoxide dismutase levels were significantly ( $P<0.001$ ) decreased in 5-FU administered rats in relation to control. The liver of 5-FU administered rats showed necrosis and steatosis. The hepatotoxic effect of 5-FU was abrogated in a dose-related fashion in RSV 10 mg/kg ( $P<0.05$ ), 20 mg/kg ( $P<0.01$ ), and 40 mg/kg ( $P<0.001$ ) supplemented rats in relation to 5-FU. RSV may be clinically effective against 5-FU-induced hepatotoxicity.

**Keywords:** 5-Fluorouracil, Liver, Toxicity, Resveratrol, Abrogate, Rat

### 1. Introduction

5-Fluorouracil (5-FU), a pyrimidine analog is clinically used as treatment for malignancies such as gastric, pancreatic, neck and breast cancers (1). Its antineoplastic effect involves activation by thymidine phosphorylase to fluorodeoxyuridine which inhibits thymidylate synthase thereby preventing DNA synthesis leading to cell death. 5-FU is also converted to active 5-fluorouridine monophosphate (5-FUMP), which inhibits RNA

function (2). The therapeutic impact of 5-FU can be incapacitated by some challenging toxicities such as myelotoxicity, leukopenia, ocular toxicity, hepatotoxicity and cardiotoxicity which are life-threatening if left untreated (3). The rising trend of hepatotoxicity due to 5-FU is becoming a significant health predicament due to detrimental impact on treatment outcomes. In some cases, lethal consequences such as death have occurred. Hepatic steatosis and fulminant hepatitis are common hepatotoxic forms of 5-FU (4). The mechanisms by which 5-FU causes hepatotoxicity are not well established, but eminent suppression of

*Corresponding Author:* Dr. Elias Adikwu, Department of Pharmacology and Toxicology Faculty of Pharmacy, Niger Delta University, Bayelsa State, Nigeria.  
Email: adikwuelias@gmail.com

hepatic antioxidant defense mechanisms and degenerative oxidation of hepatic poly unsaturated fatty acid were reported in animal studies. These observations proffer suggestive evidence of oxidative stress playing a vital role in 5-FU-induced hepatotoxicity (5, 6).

Resveratrol (RSV) is a natural polyphenol phytoalexin found in different species of plants. It is an effective antioxidant that scavenges free radicals including secondary organic radicals, which are byproducts of the interaction of biomolecules with free radicals (7). RSV can initiate and sustain oxidation-reduction balance in cells by increasing the expression of endogenous antioxidants. It can reduce the activities of enzymes that stimulate the production of free radicals such as xanthine oxidase (7) and can stimulate mitochondrial biogenesis thereby regulating mitochondrial free radical generation (8). RSV can directly react with peroxynitrite thereby reducing the nitrosylation of cysteine and tyrosine residues in proteins. It can inhibit lipid peroxidation (LPO) chain reaction by abrogating the activities of lipid peroxides produced in membrane. In addition to its antioxidant activity, it has anti-inflammatory activity, which includes reduction of cytokines overproduction, inhibition of neutrophil activity and the regulation of adhesion molecule expression (9). It also interacts with multiple molecular targets which regulates immunity by acting directly on central players of both innate and adaptive immunity, such as macrophages, lymphocytes, and dendritic cells (10). Furthermore, preclinical studies reported possible therapeutic effect of RSV in a number of disease conditions such as cardiovascular diseases, diabetes, cancer, and neurodegenerative diseases (11). RSV has shown activity as antidote in animal models of toxicities such as hepatotoxicity (12).

This study, therefore examined whether RSV may protect against a rat model of 5-FU-induced hepatotoxicity.

## 2. Materials and methods

### 2.1. Animals, drug, chemicals and treatment

Adult male albino rats (n=40), weighing 240±20 g sourced from the animal facility of the Faculty of Pharmacy, Niger Delta University, Bayelsa State, Nigeria were used. The rats were kept

5 per cage at 26 °C with 12 hours light/dark cycle, with 14 days of acclimatization prior to the experiment. The rats had *ad libitum* access to diet and water. The rats were handled according to United States National Academy of Sciences Guide for the Care and Use of Laboratory Animals. This study used RSV (10, 20 and 40 mg/kg) dissolved in normal saline (13) and 5-FU (20 mg/kg) (14). The rats were divided into eight (8) groups (A- H) of 5 rats each.

- Group A (Control) was administered with normal saline (0.2 mL/day) intraperitoneally (i.p) for 5 days.
- Groups B-D were orally administered with RSV (10, 20 and 40 mg/kg/day) for 5 days respectively.
- Group E was administered with 5-FU (20 mg/kg/day i.p) for 5 days.
- Groups F-H were orally supplemented with RSV (10, 20 and 40 mg/kg/day) prior to treatment with 5-FU (20 mg/kg/day i.p) for 5 days.

### 2.2. Animal sacrifice

On day 6, the rats were euthanized; blood samples were collected through cardiac puncture and allowed to clot. Serum fractions were separated from clots by centrifugation at 1200 rpm for 15 minutes and used for biochemical evaluations. Liver samples were harvested through dissection and rinsed in cold normal saline and homogenized in 0.1 M Tris-HCl solution buffered (pH 7.4). The homogenates were centrifuged at 4000 rpm for 20 minutes. The supernatants were collected and assessed for biochemical parameters.

### 2.3. Assessment of liver and serum biochemical markers

Serum and liver total bilirubin (TB), conjugated bilirubin (CB), aspartate aminotransferase (AST), gamma-glutamyl transferase (GGT), alanine aminotransferase (ALT), lactate dehydrogenase (LDH), and alkaline phosphatase (ALP) levels were analyzed using commercial test kits according to manufacturer's protocol.

### 2.4. Liver tissue oxidative stress marker assay

Malondialdehyde (MDA) was assayed according to Buege and Aust (1978) (15) whereas

reduced glutathione (GSH) was determined according to Sedlak and Lindsay (1968) (16). Super oxide dismutase (SOD) was assayed according to Sun and Zigman (1978) (17) whereas catalase (CAT) was evaluated as reported by Aebi 1984 (18). Glutathione peroxidase (GPx) was measured according to Rotruck et al., 1973 (19).

### 2.5. Histological analysis

The liver samples were fixed in 10% formalin saline for 24 hours and dehydrated in ascending grades of ethyl alcohol. Liver samples were embedded in paraffin and sectioned (3  $\mu$ m thickness) using a microtome. The liver sections were stained with Hematoxylin and Eosin and analyzed for histology using a light microscope.

### 2.6. Statistical analysis

Data was analyzed using one-way analysis of variance (ANOVA) followed by Tukey's test. Graph Pad Prism (Version 5.0, Graph Pad Software Inc., La Jolla, California, U.S.A.) was used for data analysis. Data are represented as mean  $\pm$  standard error of mean.  $p < 0.05$ ;  $p < 0.01$  and  $p < 0.001$  was used as significance

## 3. Results

### 3.1. Effects of on body and liver weights

Body and liver weights were normal ( $P > 0.05$ ) in RSV administered rats in relation to control. But 5-FU caused significant ( $P < 0.01$ ) decrease in body weight with significant ( $P < 0.01$ )

increase in liver weight when compared to control (Table 1). 5-FU increased relative and absolute liver weights by 56.9% and 137.3% respectively. However, supplementation with RSV 10 mg/kg ( $P < 0.05$ ), 20 mg/kg ( $P < 0.01$ ) and 40 mg/kg ( $P < 0.01$ ) restored body and liver weights in a dose-related fashion when compared to 5-FU (Table 1).

### 3.2. Effects on serum and liver tissue biochemical markers

The serum and liver levels of ALT, AST, LDH, GGT, LDH, CB and TB were normal ( $P > 0.05$ ) in RSV administered rats when compared to control (Tables 2 and 3). In contrast, the aforementioned markers were increased significantly ( $P < 0.001$ ) in 5-FU administered rats in relation to control (Tables 2 and 3). However, ALT, AST, LDH, GGT, LDH, CB and TB levels were decreased in a dose-related fashion in rats supplemented with RSV 10 mg/kg ( $p < 0.05$ ), 20mg/kg ( $p < 0.01$ ) and 40mg/kg ( $p < 0.001$ ) when compared to 5-FU administered rats (Tables 2 and 3).

### 3.3. Effects on liver oxidative stress markers and histology

Liver antioxidants (CAT, SOD, GSH, and GPX) and MDA levels were normal ( $p > 0.05$ ) in RSV administered rats in relation to control (Table 4). In contrast, liver antioxidants were significantly ( $P < 0.001$ ) decreased whereas MDA levels were significantly ( $P < 0.001$ ) increased in 5-FU administered rats in relation to control (Table 4).

**Table 1.** Effects of resveratrol on body and liver weights of 5-fluorouracil-treated albino rats

| Treatment (mg/kg) | FBW (g)            | ALW(g)            | RLW (%)           |
|-------------------|--------------------|-------------------|-------------------|
| Control           | 250.7 $\pm$ 16.0   | 5.55 $\pm$ 0.34   | 2.44 $\pm$ 0.08   |
| RSV 10            | 245.9 $\pm$ 14.9   | 5.57 $\pm$ 0.45   | 2.27 $\pm$ 0.06   |
| RSV 20            | 250.0 $\pm$ 13.8   | 5.50 $\pm$ 0.27   | 2.20 $\pm$ 0.07   |
| RSV 40            | 246.5 $\pm$ 17.7   | 5.47 $\pm$ 0.56   | 2.22 $\pm$ 0.02   |
| 5-FU              | 150.4 $\pm$ 13.4#  | 8.71 $\pm$ 0.47#  | 5.79 $\pm$ 0.34#  |
| RSV 10+5-FU       | 170.6 $\pm$ 12.7   | 8.35 $\pm$ 0.52   | 4.89 $\pm$ 0.27*  |
| RSV 20+5-FU       | 230.9 $\pm$ 15.5*  | 6.99 $\pm$ 0.68*  | 3.03 $\pm$ 0.14** |
| RSV 40+5-FU       | 250.1 $\pm$ 17.2** | 5.71 $\pm$ 0.11** | 2.28 $\pm$ 0.30** |

Data as mean  $\pm$  SEM, n=5, RSV: Resveratrol, 5-FU: 5-Fluorouracil, FBW: Final body weight ALW: Absolute liver weight, RLW: Relative liver weight, # $P < 0.01$  when compared to control, \* $P < 0.05$  when compared to 5-FU, \*\* $P < 0.01$  when compared to 5-FU

**Table 2.** Effect of resveratrol on serum biochemical parameters of 5-fluorouracil administered rats

| Treatments (mg/kg) | AST(U/L)   | ALT(U/L)    | ALP(U/L)   | GGT(U/L)   | CB(g/dL)    | TB(g/dL)     | LDH(U/L)   |
|--------------------|------------|-------------|------------|------------|-------------|--------------|------------|
| Control            | 22.1±2.82  | 25.9±2.52   | 25.4±2.55  | 0.27±0.03  | 2.56±0.10   | 4.72±0.09    | 27.6±2.19  |
| RSV 10             | 23.7±2.53  | 24.7± 2.50  | 25.0±2.78  | 0.26±0.01  | 2.53±0.07   | 4.64±0.36    | 27.0±2.88  |
| RSV 20             | 21.4±2.48  | 24.8±2.62   | 23.7±2.05  | 0.24±0.07  | 2.49±0.07   | 4.56±0.37    | 26.6±2.97  |
| RSV 40             | 22.3±2.54  | 23.5±3.68   | 24.3±2.15  | 0.23±0.02  | 2.48±0.07   | 4.50±0.06    | 26.0±2.92  |
| 5-FU 20            | 71.2±5.40a | 75.1±6.74a  | 70.3±6.62a | 1.00±0.09a | 8.51±0.15a  | 11.97±0.76 a | 87.2±6.92a |
| RSV 10+5-FU 20     | 50.4±3.97b | 54.0±5.15 b | 50.7±4.34b | 0.40±0.06b | 6.10±0.12b  | 9.90±0.51b   | 61.2±5.37b |
| RSV20+5-FU 20      | 40.0±3.54c | 37.2±3.35c  | 39.1±2.53  | 0.61±0.08c | 4.05±0.34 c | 6.93±0.14 c  | 40.2±3.12c |
| RSV40+5-FU 20      | 23.1±2.93  | 26.2±2.03d  | 27.9±2.56d | 0.30±0.01d | 2.60±0.47d  | 4.80±0.32d   | 29.3±2.28d |

AST: Aspartate aminotransferase, ALT: Alanine aminotransferase, ALP: Alkaline phosphatase, GGT: Gamma glutamyltransferase, TB: Total bilirubin, CB: Conjugated bilirubin, LDH: Lactate dehydrogenase, 5-FU: 5-Fluorouracil RSV: Resveratrol, n= 5, Data expressed as Mean ± SEM. a P<0.001 when compared to control. b P<0.05 when compared to 5-FU. c P<0.01 when compared to 5-FU. d P<0.001 when compared to 5-FU

However, liver antioxidants were significantly increased whereas MDA levels were significantly decreased in a dose-related fashion in RSV 10 mg/kg ( $p<0.05$ ), 20mg/kg ( $p<0.01$ ) and 40mg/kg ( $p<0.001$ ) supplemented rats when compared to 5-FU (Table 4). The liver of control rat showed normal hepatocytes (Figure A). The liver of 5-FU administered rats showed hepatocyte necrosis (Figure B) and micro vascular steatosis (Figure C). The liver of rats supplemented with RSV (10 mg/kg) showed severe hepatocyte distortion (Figure D) whereas the liver of rats supplemented with RSV (20mg/kg) (Figure E) and RSV (40 mg/kg) (Figure F) showed mild hepatocyte distortions.

#### 4. Discussion

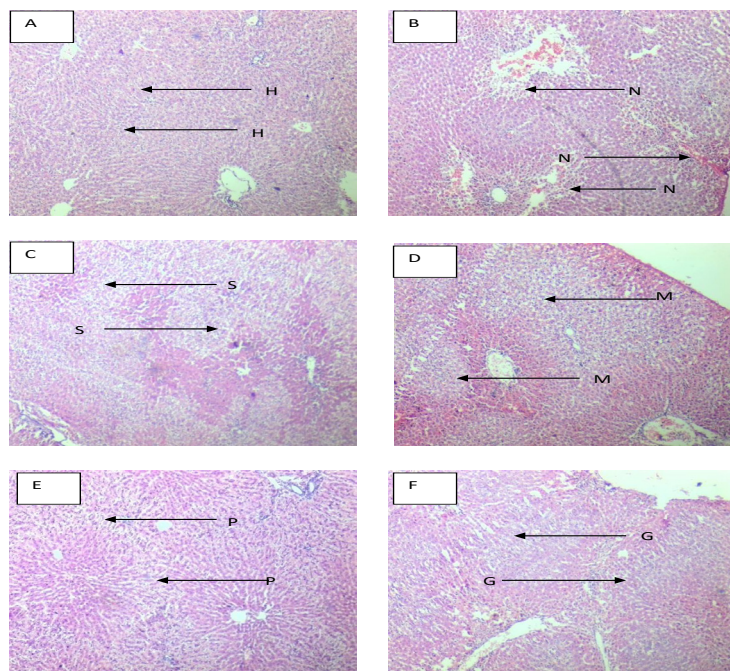
5-FU is one of the primary options for cancer treatment, but treatment outcomes and survival rate can be jeopardized by the occurrence of hepatotoxicity which has limited treatment options (20). Preclinical studies have shown that natural antioxidants have potential as excellent treatment for diseases, such as diabetes, hypertension, cancer and drug-induced toxicities (21). This study examined the protective effect of RSV against a rat model of 5-FU-induced hepatotoxicity. Perturbation in organ weight may occur with the advent of drug-induced toxicity (22). In the current

**Table 3.** Effects of resveratrol on liver tissue biochemical parameters of 5-fluorouracil administered albino rats

| Treatment (mg/kg) | AST(U/L)     | ALT(U/L)     | ALP(U/L)     | GGT(U/L)    | LDH(U/L)     |
|-------------------|--------------|--------------|--------------|-------------|--------------|
| Control           | 225.8±14.4   | 223.0±12.37  | 221.8±16.4   | 26.9±3.49   | 216.4±13.4   |
| RSV 10            | 219.9±12.6   | 221.3±11.4   | 220.6±14.2   | 24.0±2.68   | 214.0±15.1   |
| RSV 20            | 218.4±12.5   | 219.7±14.8   | 213.8±12.4   | 23.2±2.80   | 208.3±14.7   |
| RSV 40            | 213.3±11.7   | 215.3±12.7   | 215.3±14.9   | 24.3±3.92   | 210.1±13.4   |
| 5-FU 20           | 847.5±18.7 a | 872.0±16.3 a | 730.8±14.2 a | 83.5±7.06 a | 868.5±15.8 a |
| RSV 10+5-FU20     | 584.6±14.6 b | 570.4±13.6 b | 548.8±17.9 b | 54.9±4.42 b | 532.4±15.0 b |
| RSV 20+5-FU20     | 364.2±14.3 c | 384.7±14.8 c | 380.16±3.3 c | 36.2±3.86c  | 342.3±16.7 c |
| RSV40+5-FU20      | 246.8±12.3 d | 235.0±12.5 d | 230.0±13.9 d | 27.1±3.48   | 233.6±15.9 d |

AST: Aspartate aminotransferase, ALT: Alanine aminotransferase, ALP: Alkaline phosphatase, GGT: Gamma-glutamyltransferase, LDH: Lactate dehydrogenase, 5-FU: 5-Fluorouracil and RSV: Resveratrol. n=5, Data expressed as Mean ± SEM. a P<0.001 when compared to control. b P<0.05 when compared to 5-FU. c P<0.01 when compared to 5-FU. d P<0.001 when compared to 5-FU.





**Figure 1.** Normal hepatocyte (H) was observed in the control liver (Figure A). Hepatocyte necrosis (N) (Figure B) and micro vascular steatosis (S) (Figure C) were observed in 5-FU administered rats. Severe hepatocyte distortion (M) was observed in RSV (10 mg/kg) supplemented rats (Figure D). Mild hepatocyte distortion (P) was observed in RSV (20 mg/kg) supplemented rats (Figure D). Mild hepatocyte distortion (G) was observed in RSV (40 mg/kg) supplemented rats (Figure F). H and E×100

study, body and liver weights were normal in RSV administered rats. In contrast, decrease in body weight with increase in liver weight were observed in 5-FU administered rats. The observed increase in liver weight is in agreement with earlier reports (14). This could be attributed to the induction of inflammation by 5-FU which is one of its speculated hepatotoxic mechanisms (23). On the

other hand, supplementation with RSV restored body and liver weights in a dose-related fashion. The restored liver weight may be attributed to the anti-inflammatory activity of RSV. Hepatic membrane damage leads to increased serum levels of biochemical markers such as ALT, AST, and LDH, GGT, LDH, CB and TB. The aforementioned biochemical markers are employed regularly to ascer-

**Table 4.** Effect of resveratrol on liver oxidative stress markers of 5-fluorouracil administered rats.

| Treatment (mg/kg) | SOD (U/mg protein) | CAT (U/mg protein) | GSH ( $\mu$ mole/mg protein) | MDA (nmole/mgprotein) | GPx (U/mg protein) |
|-------------------|--------------------|--------------------|------------------------------|-----------------------|--------------------|
| Control           | 41.3±2.21          | 59.1±3.72          | 17.0±1.80                    | 0.27±0.01             | 18.6 ± 1.04        |
| RSV 10            | 42.1±3.80          | 59.3±3.31          | 18.0±1.46                    | 0.25±0.01             | 18.7 ± 1.80        |
| RSV 20            | 43.1±4.76          | 60.4±6.49          | 18.3±1.38                    | 0.24±0.01             | 19.0 ± 1.85        |
| RSV 40            | 45.4±3.74          | 63.8±5.89          | 19.7±1.84                    | 0.21±0.01             | 20.9 ± 1.87        |
| 5-FU 20           | 12.3±1.41a         | 19.1±1.58 a        | 4.71±0.10 a                  | 0.99±0.03 a           | 5.56 ± 0.08 a      |
| RSV 10+5-FU 20    | 19.5±0.41 b        | 30.4±2.71 b        | 7.73±0.05 b                  | 0.54±0.01 b           | 7.73 ± 0.04b       |
| RSV 20+5-FU 20    | 26.9±2.73 c        | 41.7±4.62 c        | 10.5±0.22 c                  | 0.33±0.01 c           | 11.1 ± 0.19 c      |
| RSV 40+5-FU 20    | 39.6±3.93d         | 57.7±5.68 d        | 15.3±1.84 d                  | 0.21±0.01 d           | 16.1 ± 1.61 d      |

SOD : Superoxide dismutase, CAT: Catalase, GSH: Glutathione,MDA: Malondialdehyde, GPx: Glutathione peroxidase, 5-FU: 5-Fluorouracil RSV: Resveratrol, n= 5, Data expressed as Mean ± SEM. a P<0.001 when compared to control. b P<0.05 when compared to 5-FU. c P<0.01 when compared to 5-FU. dP<0.001 when compared to 5-FU

tain the well being of the liver. In the current study, serum and liver ALT, AST, LDH, GGT, LDH, CB and TB levels were normal in RSV administered rats. In contrast, the aforementioned parameters were elevated in 5-FU-administered rats. The observation in 5-FU administered rats is consistent with earlier report (24). However, the serum and liver levels of ALT, AST, and LDH, GGT, LDH, CB and TB were restored in a dose-related fashion in RSV supplemented rats. Antioxidants are essential defensive mechanisms that prevent the induction of oxidative stress by ROS. In the fight against oxidative stress, antioxidants can be overwhelmed and depleted by excess and uncontrollable ROS production (25). In the current study, the administration of RSV had no effects on hepatic antioxidants (CAT, SOD, GSH and GPx). On the other hand, the administration of 5-FU led to hepatic antioxidant depletion marked by decreased CAT, SOD, GSH and GPx levels. The observation in 5-FU administered rats is consistent with previous finding (26). However, RSV supplementation increased hepatic antioxidant levels in a dose-dependent fashion.

LPO, an oxidative deterioration of polyunsaturated fatty acid is a consequence of ROS-induced reaction, which has been implicated in pathogenic processes associated with some disease conditions. The involvement of LPO in pathologic processes can be established by the measurements of its by-products such as MDA, and 4-hydroxynonenal. The current study assayed MDA as an index for hepatic LPO (27). MDA levels were normal in rats administered with RSV. In contrast, MDA level was increased in 5-FU administered rats. This observation is a sign of hepatic LPO, which is in resonance with earlier reports (28).

However, RSV supplementation produced marked reductions in MDA levels in a dose-dependent fashion. Pathologic changes that occur in 5-FU-induced hepatotoxicity could be characterized by alterations in liver histology such as hepatocyte necrosis and steatosis (28, 29). This study observed hepatocyte necrosis and steatosis in 5-FU administered rats. However, RSV supplementation ameliorates the aforementioned histological changes. The precise mechanism of 5-FU-induced hepatotoxicity is not well understood. However,

this study observed decreased antioxidants and increased MDA levels in 5-FU-administered rats which suggest that oxidative stress and LPO are possible mechanisms of 5-FU-induced hepatotoxicity. Similarly, some studies have correlated 5-FU-induced hepatotoxicity with oxidative stress (29, 30). Oxidative stress can damage the integrity of biomolecules including lipids, proteins and DNA (31). LPO can influence membrane fluidity as well as the integrity of biomolecules associated with membrane (membrane bound proteins or cholesterol). Highly oxidizable lipids can attack surrounding proteins causing the formation of excess protein carbonyls and other adducts in cells (32). Adducts formed in cells, can deposit in clumps and inactivate normal cellular function. RSV might have prevented 5-FU-induced hepatotoxicity through its antioxidant and anti-inflammatory activities. RSV is an effective scavenger of ROS and reactive nitrogen species (RNS) as well as other secondary organic radicals produced during the reaction of biomolecules with ROS and RNS (33). It can increase the expression of some endogenous antioxidant enzymes that maintain oxidation-reduction balance in cells (34, 35).

It can also reduce the activities of enzymes which play dominant roles in ROS production, such as xanthine oxidase (36). RSV's strong ability to scavenge free radicals is related to presence of three hydroxyl groups in positions 3, 4' and 5, as well as the presence of aromatic rings and a double bond in its molecule (7). In this study, RSV might have inhibited LPO by removing lipid peroxides and other radicals produced in hepatic membranes (37).

## 5. Conclusion

This study suggests that RSV may have clinical benefit in 5-FU-induced hepatotoxicity.

## Acknowledgments

The authors appreciate the handling of animals by Mr Cosmos Obi of the Department of Pharmacology and Toxicology, Faculty of Pharmacy, Niger Delta University, Nigeria

## Conflict of Interest

None declared.

## References

1. Yousef HN, Aboelwafa HR. The potential protective role of taurine against 5-fluorouracil-induced nephrotoxicity in adult male rats. *Exp Toxicol Pathol.* 2017 Jun 14;69(5):265-274. doi: 10.1016/j.etp.2017.01.012. Epub 2017 Feb 8. PMID: 28189472.
2. Nadia R.A. Abou-Zeid. Ameliorative effect of vitamin C against 5-fluorouracil-induced hepatotoxicity in mice: A light and electron microscope study. *J Basic Appl Zool.* 2014;67:109-18
3. Focaccetti C, Bruno A, Magnani E, Bartolini D, Principi E, Dallaglio K, Bucci EO, Finzi G, Sessa F, Noonan DM, Albin A. Effects of 5-fluorouracil on morphology, cell cycle, proliferation, apoptosis, autophagy and ROS production in endothelial cells and cardiomyocytes. *PLoS One.* 2015 Feb 11;10(2):e0115686. doi: 10.1371/journal.pone.0115686. PMID: 25671635; PMCID: PMC4324934.
4. Hajj A, Ghosn M, Mourad D, Hojaiban K, Mousallem P, Khabbaz LR. Lethal hepatotoxicity following 5-fluorouracil/cisplatin chemotherapy: a relevant case report. *Per Med.* 2017 May;14(3):197-201. doi: 10.2217/pme-2016-0085. Epub 2017 May 5. PMID: 29767581.
5. Fukuno S, Nagai K, Yoshida S, Suzuki H, Konishi H. Taurine as a protective agent for 5-fluorouracil-induced hepatic damage related to oxidative stress. *Pharmazie.* 2016 Sep 1;71(9):530-532. doi: 10.1691/ph.2016.6611. PMID: 29441849.
6. Ray S, Roy K, Sengupta C. In vitro evaluation of protective effects of ascorbic acid and water extract of *Spirulina plantesis* (blue green algae) on 5-fluorouracil-induced lipid peroxidation. *Acta Pol Pharm.* 2007 Jul-Aug;64(4):335-44. PMID: 18536159.
7. Gerszon J, Rodacka A, Puchała M. Antioxidant properties of resveratrol and its protective effects in neurodegenerative diseases. *Med J Cell Biol.* 2014;4:97-117.
8. Beauloye C, Bertrand L, Horman S, Hue L. AMPK activation, a preventive therapeutic target in the transition from cardiac injury to heart failure. *Cardiovasc Res.* 2011 May 1;90(2):224-33. doi: 10.1093/cvr/cvr034. Epub 2011 Feb 1. PMID: 21285292.
9. Liu FC, Tsai YF, Tsai HI, Yu HP. Anti-Inflammatory and Organ-Protective Effects of Resveratrol in Trauma-Hemorrhagic Injury. *Mediators Inflamm.* 2015;2015:643763. doi: 10.1155/2015/643763. Epub 2015 Jul 26. PMID: 26273141; PMCID: PMC4529946.
10. Švajger U, Jeras M. Anti-inflammatory effects of resveratrol and its potential use in therapy of immune-mediated diseases. *Int Rev Immunol.* 2012 Jun;31(3):202-22. doi: 10.3109/08830185.2012.665108. PMID: 22587021.
11. Xia N, Daiber A, Förstermann U, Li H. Antioxidant effects of resveratrol in the cardiovascular system. *Br J Pharmacol.* 2017;174(12):1633-1646. doi:10.1111/bph.13492
12. Singh D, Cho WC, Upadhyay G. Drug-Induced Liver Toxicity and Prevention by Herbal Antioxidants: An Overview. *Front Physiol.* 2016 Jan 26;6:363. doi: 10.3389/fphys.2015.00363. PMID: 26858648; PMCID: PMC4726750.
13. Radwan OK, Ahmed RF. Amendment effect of resveratrol on diclofenac idiosyncratic toxicity: Augmentation of the anti-inflammatory effect by assessment of Arachidonic acid and IL-1 $\beta$  levels. *J App Pharm Sci.* 2016;6(12):170-7.
14. Gelen V, Şengül E, Yıldırım S, Atila G. The protective effects of naringin against 5-fluorouracil-induced hepatotoxicity and nephrotoxicity in rats. *Iran J Basic Med Sci.* 2018 Apr;21(4):404-410. doi: 10.22038/IJBMS.2018.27510.6714. PMID: 29796225; PMCID: PMC5960758.
15. Buege JA, Aust SD. Microsomal lipid peroxidation. *Methods Enzymol.* 1978;52:302-10. doi: 10.1016/s0076-6879(78)52032-6. PMID: 672633.
16. Sedlak J, Lindsay RH. Estimation of total, protein-bound, and nonprotein sulfhydryl groups in tissue with Ellman's reagent. *Anal Biochem.* 1968 Oct 24;25(1):192-205. doi: 10.1016/0003-2697(68)90092-4. PMID: 4973948.
17. Sun M, Zigman S. An improved spectrophotometric assay for superoxide dismutase based on epinephrine autoxidation. *Anal Biochem.* 1978 Oct 1;90(1):81-9. doi: 10.1016/0003-2697(78)90010-6. PMID: 727489.
18. Aebi H. Catalase in vitro. *Methods Enzymol.* 1984;105:121-6. doi: 10.1016/s0076-6879(84)05016-3. PMID: 6727660.
19. Rotruck JT, Pope AL, Ganther HE, Swanson AB, Hafeman DG, Hoekstra WG. Selenium: biochemical role as a component of glutathione peroxidase. *Science.* 1973 Feb 9;179(4073):588-90. doi: 10.1126/science.179.4073.588. PMID:



4686466.

20. El-Hoseany NMA. Protective effect of captopril against 5-fluorouracil-induced hepato and nephrotoxicity in male albino rats. *J Am Sci*. 2013;8:680-685

21. Thriveni V, Manjunatha H, Santhosh KH. Hepatoprotective Effect of Curcumin and Capsaicin against Lipopolysaccharide Induced Liver Damage in Mice. *Pharmacog J*. 2017;9(6):947-51.

22. Adikwu E, Nelson EC, Fiyebbo P. Selenium as a therapeutic adjuvant for isoniazid/rifampicin-induced hepatotoxicity. *BLDE Univ J Health Sci*. 2020;5:60-7.

23. Marra F, Tacke F. Roles for chemokines in liver disease. *Gastroenterology*. 2014 Sep;147(3):577-594.e1. doi: 10.1053/j.gastro.2014.06.043. Epub 2014 Jul 25. PMID: 25066692.

24. Dimitriu D, Lupusoru C, Cojocaru I, Gafitanu C, Palade L, Lupusoru R. Assessing biochemical and oxidative stress parameters after vaginal and oral administration of 5-fluorouracil in laboratory animals. *Farmacia*. 2015;63:230-3.

25. Adikwu E, Braimbaifa N, Obianime AW. Melatonin and Alpha Lipoic Acid: Possible Mitigants for Lopinavir/Ritonavir- Induced Renal Toxicity in Male Albino Rats. *Physiol Pharmacol*. 2016;19:232-40.

26. Behling EB, Sendão MC, Francescato HD, Antunes LM, Costa RS, Bianchi Mde L. Comparative study of multiple dosage of quercetin against cisplatin-induced nephrotoxicity and oxidative stress in rat kidneys. *Pharmacol Rep*. 2006 Jul-Aug;58(4):526-32. PMID: 16963799.

27. Grotto D, Maria SL, Valentini J, Paniz C, Schmitt G, Garcia SC. Importance of the lipid peroxidation biomarkers and methodological aspects FOR malondialdehyde quantification. *Quím. Nova*. 2009;32(1):169-174.

28. El-Sayyad HI, Ismail MF, Shalaby FM, et al. Histopathological effects of cisplatin, doxorubicin and 5-fluorouracil (5-FU) on the liver of male albino rats. *Int J Biol Sci*. 2009;5(5):466-473. Published 2009 Jun 28. doi:10.7150/ijbs.5.466

29. Gelen V, Şengül E, Gedikli S, Atila G,

Uslu H, Makav M. The protective effect of rutin and quercetin on 5-FU-induced hepatotoxicity in rats. *Asian Pac J Trop Biomed*. 2017;7:647-653.

30. Al-Asmari AK, Khan AQ, Al-Masri N. Mitigation of 5-fluorouracil-induced liver damage in rats by vitamin C via targeting redox-sensitive transcription factors. *Hum Exp Toxicol*. 2016 Nov;35(11):1203-1213. doi: 10.1177/0960327115626583. Epub 2016 Jul 11. PMID: 26921358.

31. Almroth BC, Sturve J, Berglund A, Förlin L. Oxidative damage in eelpout (*Zoarces viviparus*), measured as protein carbonyls and TBARS, as biomarkers. *Aquat Toxicol*. 2005 Jun 15;73(2):171-80. doi: 10.1016/j.aquatox.2005.03.007. Epub 2005 Apr 13. PMID: 15917092.

32. Afolabi OK, Adeleke GE, Ugbaja RN. Crocin Alleviates 5-Fluorouracil-induced Hepatotoxicity through the abrogation of Oxidative Stress in Male Wistar rats. *Asian Pac J Health Sci*. 2016;3(2):58-68

33. Cordova-Gomez M, Galano A, Raul J, Alvarez-Idaboy JR. Piceatannol, a better peroxyl radical scavenger than resveratrol. *RSC Adv*. 2013;3:20209-20218

34. Kavas GO, Ayril PA, Elhan AH. The effects of resveratrol on oxidant/antioxidant systems and their cofactors in rats. *Adv Clin Exp Med*. 2013 Mar-Apr;22(2):151-5. PMID: 23709370.

35. KKincaid B, Bossy-Wetzel E. Forever young: SIRT3 a shield against mitochondrial meltdown, aging, and neurodegeneration. *Front Aging Neurosci*. 2013;5:48. Published 2013 Sep 6. doi:10.3389/fnagi.2013.00048

36. Robb EL, Page MM, Wiens BE, Stuart JA. Molecular mechanisms of oxidative stress resistance induced by resveratrol: Specific and progressive induction of MnSOD. *Biochem Biophys Res Commun*. 2008 Mar 7;367(2):406-12. doi: 10.1016/j.bbrc.2007.12.138. Epub 2007 Dec 31. PMID: 18167310.

37. Tadolini B, Juliano C, Piu L, Franconi F, Cabrini L. Resveratrol inhibition of lipid peroxidation. *Free Radic Res*. 2000 Jul;33(1):105-14. doi: 10.1080/10715760000300661. PMID: 10826926.