


Descriptive Report of Microorganisms Detected in Cultures of COVID-19 Patients Developing Secondary Infection After Tocilizumab Use

Dena Firouzabadi^{1,2*} ; Ph.D, Sahar DehghanKhalili³; MD, Saeed DehghanKhalili⁴; MD

¹Department of Clinical Pharmacy, School of Pharmacy, Shiraz University of Medical Sciences, Shiraz, Iran.

²Shahid Faghihi Hospital, Shiraz University of Medical Sciences Shiraz, Iran.

³School of Medicine, Shiraz University of Medical Sciences, Shiraz, Iran.

⁴Ophthalmology Department, School of Medicine, Shiraz University of Medical Sciences, Shiraz, Iran.

Abstract

Tocilizumab an anti-inflammatory medication previously approved for the treatment of rheumatoid arthritis, was widely used during the COVID-19 pandemic. Secondary infections following the use of tocilizumab were expected knowing its inhibitory effect on the cascade of inflammation by blocking IL6. Patterns of microorganism growth in positive culture reports after tocilizumab use have not been widely assessed in the literature. In this retrospective study, we included all patients diagnosed with severe COVID-19 admitted to the intensive care unit (ICU). Patients were divided into two groups; tocilizumab receivers and non-receivers. Patient records were evaluated for the presence of positive culture results. Patterns of microorganism growth and their sensitivity to antibiotics were assessed and compared between the two groups. Seventy-seven patients (74.8%) in the tocilizumab group developed secondary infection, irrespective of the culture origin. The rate of positive culture result was significantly higher in the group treated with tocilizumab (P-value 0.022). *Candida* and *Acinetobacter* species were the most common microorganisms detected in sputum cultures, *Candida* and *Escherichia coli* (*E. coli*) species were dominant in urine cultures, and methicillin-resistant *Staphylococcus Aureus* (MRSA), *Acinetobacter* and *Candida* species were the leading microorganisms of positive blood cultures. No significant difference was observed in the culture growth patterns in both groups. The presence of multi-drug resistant nosocomial microorganisms in ICU-admitted COVID-19 patients may be associated with causes other than tocilizumab use and may lead to poor patient outcomes.

Keywords: COVID-19, Tocilizumab, Secondary Infections, Microorganisms, Bacterial infections, Fungal infections.

Please cite this article as: Firouzabadi D*, DehghanKhalili S, DehghanKhalili S. Descriptive Report of Microorganisms Detected in Cultures of COVID-19 Patients Developing Secondary Infection After Tocilizumab Use. Trends in Pharmaceutical Sciences. 2024;10(3):241-250. doi: 10.30476/tips.2024.103619.1252

Copyright: ©Trends in Pharmaceutical Sciences. This is an open-access article distributed under the terms of the Creative Commons Attribution-NoDerivatives 4.0 International License. This license allows reusers to copy and distribute the material in any medium or format in unadapted form only, and only so long as attribution is given to the creator. The license allows for commercial use.

1. Introduction

At the beginning of COVID-19 viral infection in China, symptoms detected were mostly non-specific respiratory symptoms such as cough,

shortness of breath, and dyspnea along with fever as an accompanying presentation (1). With the worldwide distribution of the infection and its further evolution, soon other clinical presentations including gastrointestinal, cardiac, neurological, and many other organ involvements were detected. However, its main features remained fever and pneumonia ultimately leading to the patient's

Corresponding Author: Dena Firouzabadi, Department of Clinical Pharmacy, School of Pharmacy, Shiraz University of Medical Sciences, Shiraz, Iran
Email address: denaf9@yahoo.com

hospital admission (2-5). Although the majority of COVID-19 cases exhibited a mild and uncomplicated course, approximately 10-15% of patients experienced moderate to severe disease, necessitating hospitalization and oxygen supplementation. Furthermore, 3-5% of individuals were likely to require admission to the intensive care unit (ICU) (6). Severe complications were frequently observed in COVID-19 patients, with acute respiratory distress syndrome (ARDS) being one of the most prominent ones. (7). Approximately 29% of patients developed ARDS, and a significant proportion (32%) required admission to the ICU specifically during the Delta variant peak (8).

Pathogenesis of the virus includes a dysregulated cytokine release with IL-6 and TNF- α being prominently expressed contributing to the cytokine storm, known as the main mechanism involved in ARDS leading to a patient's critical respiratory conditions (5). As IL-6 plays a pivotal role in the propagation of subsequent signaling pathways of inflammation, (9) it was aimed as a viable target for drug therapy of the viral infection. The deadly outbreak of COVID-19 viral infection led to the discovery of many new medications for the intention of COVID-19 treatment or alleviation of its symptoms. Some other drugs already present in the pharmaceutical market were also repurposed based on their mechanisms of action during the pandemic and their effectiveness was evaluated in different studies. Tocilizumab was one of the repurposed medications introduced and widely used worldwide during the deadly Delta variant peak of COVID-19 infection after the prominent role of IL-6 in the severity of the disease was discovered (10-12). This medication had previously been approved for the treatment of rheumatoid arthritis (RA) as a disease-modifying agent (13). One major problem with tocilizumab is its risk of developing secondary infections as observed in both RA and COVID-19 patients (14, 15). The increased rate and clinical significance of secondary infections in COVID-19 patients treated with tocilizumab have not been unanimously supported in the literature but many studies have confirmed tocilizumab's role in increasing rates of secondary infection (14, 16). However, data regarding the types of microorganisms grown in positive cultures has not been much investigated. In this retrospective study, we evaluated the rate

of secondary infections and the growth pattern of different microorganisms in the positive culture reports of ICU-admitted COVID-19 patients in whom tocilizumab was administered compared to ICU-admitted patients in whom tocilizumab was not used as a COVID-19 treatment option.

2. Material and methods

In this retrospective study, all patients with PCR-confirmed COVID-19 infection, admitted to the intensive care unit (ICU) due to their critical respiratory condition, were included. The study population was gathered from the largest referral COVID-19 hospital in Shiraz, Shahid Faghihi Hospital, affiliated to the Shiraz University of Medical Sciences, during the period of the deadly emergence of the Delta variant of the virus (March to December 2021). The study was carried out according to the Declaration of Helsinki principles for research in human subjects and was approved by the university's ethics committee (ethics code: IR.SUMS.MED.REC.1402.124). Inclusion criteria for this study were as follows: patients older than 18 years of age, with PCR-confirmed diagnosis of COVID-19 infection with severity of disease having been admitted to the ICU that were admitted for longer than 5 days in the ICU for which culture samples were referred to the laboratory. Also, the use of tocilizumab was considered an inclusion criterion for the patients in the case group. Patients with severe COVID-19 infection with no culture samples obtained during their ICU stay were excluded from the total study population and patients with contraindications to receiving tocilizumab were also excluded from the case group.

Patients were divided into two groups including those who received tocilizumab during their COVID-19 infection and ICU admitted subjects without a positive history of tocilizumab use. Patients' admission documents and electronic records were evaluated for the presence of culture results during their ICU stay and after the use of tocilizumab in the group with a history of tocilizumab use. Types of positive cultures and a detailed description of the microorganisms detected in the cultures were documented for both groups and compared between the two. Each sample depending on its site of collection and its preliminary gram staining result, was cultured on a set of specific culture media plates, and depending on its

growth pattern, color, shape, and size of colonies, the specific species responsible for the positive culture result is suggested by the laboratory expert. Subsequently, media with positive microorganism growth were subcultured onto specific plates for susceptibility testing with disk diffusion method according to Clinical and Laboratory Standards Institute (CLSI) protocols. The isolated bacteria were reported to be resistant, intermediately resistant, or sensitive according to the size of the inhibition zone resulting from the disk diffusion method (17, 18).

Statistical analysis was performed by using the IBM SPSS version 26.0. Qualitative variables were reported as frequency and percentage. The association between qualitative variables and tocilizumab use was evaluated using the Chi-squared test or Fisher's exact test. P values less than 0.05 were considered statistically significant.

3. Results and discussion

In this retrospective study, 216 patients with a mean age of 54.86 ± 15.77 years were included. A total of 118 patients received tocilizumab during their ICU stay and 98 individuals did not receive this agent. The mean ages of the two groups were comparable, being 53.96 ± 14.66 and 55.91 ± 17.08 years, respectively.

A total of 131 patients (67.2%) showed a positive culture result in the whole study population, irrespective of the culture origin. The rate of positive culture result was significantly higher in tocilizumab receivers ($P=0.022$). In the total study population, positive results were reported from blood, urine, and sputum cultures in 25.3%, 51.7%, and 71.5% of patients, respectively. Ac-

ording to the results, the total rate of secondary infection in tocilizumab receivers was 74.8%.

The most common microorganism detected in sputum cultures among recipients and non-recipients of tocilizumab was *Acinetobacter* species (31.3% and 48.7%, respectively). Of note, the rate of aspergillosis, methicillin-resistant *Staphylococcus aureus* (MRSA), and *S. aureus* isolates were higher in the tocilizumab group. Urine culture results indicate dominance of *Candida* species in both groups (64% and 56.7% in tocilizumab recipients and non-recipients, respectively). Blood culture results indicate high rates of MRSA (30%) and *Acinetobacter* (20%) infection in the tocilizumab recipients and dominance of *Acinetobacter* species (40%) in patients in the control group with positive blood culture results.

The most common microorganisms detected in sputum cultures amongst tocilizumab recipients were *Acinetobacter* (31.3%), *Candida* species (28.1%) and *Klebsiella* (15.6%). The same pattern was observed for the control group, but with slightly different frequencies of 48.7%, 30.8%, and 15.6%, respectively. Of note, rates of aspergillosis, MRSA, and *S. aureus* were higher in subjects who received tocilizumab (Figure 1).

Available antibiogram data of positive sputum cultures reveal that all cultures with reports of *Acinetobacter* species except for one were sensitive to colistin. The only one resistant to colistin was also not sensitive to imipenem, ceftriaxone, gentamycin, and amikacin. All *Klebsiella* species were sensitive to imipenem, ciprofloxacin, amikacin and gentamycin. All MRSA-positive cultures were sensitive to vancomycin and rifampin. Some *S. aureus*-positive cultures were sensitive to ce-

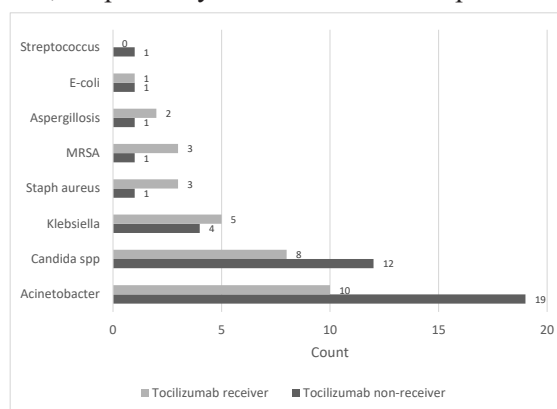


Figure 1. Microorganisms detected in sputum cultures in patients with severe COVID-19 who received and did not receive tocilizumab.

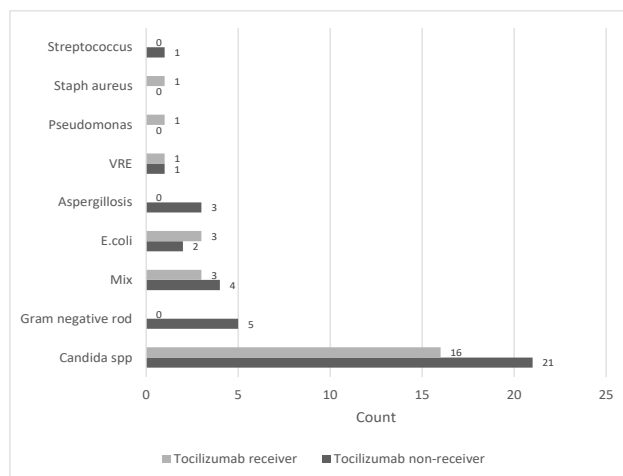


Figure 2. Microorganisms detected in urine cultures in patients with severe COVID-19 who received (case group) and did not receive (control group) tocilizumab.

fazolin and vancomycin, but resistant to clindamycin. *Pseudomonas* cultures were resistant to carbapenems, amikacin, and cefixime but sensitive to colistin.

The most common microorganisms detected in urine cultures amongst cases were *Candida* species (64%), and *E. coli* (12%). The most common microorganisms detected in urine cultures amongst controls were *Candida* species (56.7%) and gram-negative rods (13.5%) (Figure 2). Since Germ tube test used for defining *Candida albicans* from the non-*albicans* spp. was not performed for all samples, results of *Candida* spp. growth were reported non-specifically and the number *C. albicans* spp. vs *C. non-albicans* spp. could not be defined in this study. Amongst the gram-negative rods reported, three were extended broad spectrum beta-lactamase producing (ESBL) species showing resistance to ceftriaxone, cefepime, imipenem and ampicillin-sulbactam and one showed multi-drug resistance patterns (MDR) with resistance to

amikacin, gentamycin, ciprofloxacin, imipenem, ceftriaxone, cefepime, and ampicillin-sulbactam.

Available antibiogram data of positive urine cultures reveal *E. coli* species growth that was sensitive to amikacin and resistant to imipenem. All of the vancomycin-resistant enterococcus (VRE) positive cultures were sensitive to amikacin, gentamicin, and imipenem.

The most common microorganisms detected in blood cultures amongst tocilizumab users were MRSA (30%) and *Acinetobacter* (20%). The most common microorganism detected in blood cultures amongst controls was *Acinetobacter* (40%) (Figure 3).

Available antibiogram data of positive blood cultures reveal the following sensitivity patterns: *Acinetobacter* species were sensitive to colistin, MRSA positive cultures showed sensitivity patterns to vancomycin and rifampin. *Pseudomonas* species found in blood cultures were sensitive to colistin and resistant to ciprofloxacin,

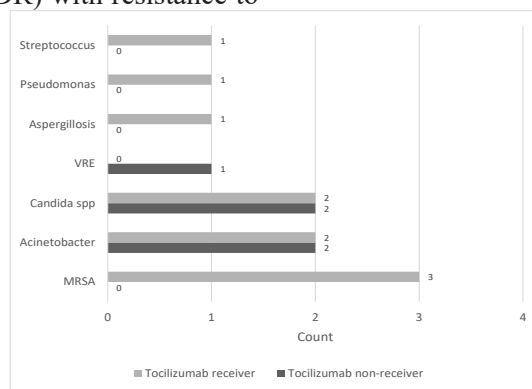


Figure 3. Microorganisms detected in blood cultures in patients with severe COVID-19 who received (case group) and did not receive (control group) tocilizumab.

gentamycin, amikacin, and imipenem. Streptococcus species were sensitive to vancomycin. Details of resistance and sensitivity patterns of available positive cultures of patients with a history of tocilizumab use has been brought in Table 1.

To be able to perform a statistical analysis to compare the distribution of microorganisms detected in each type of culture between tocilizumab

receivers and non-receivers, sputum cultures were categorized into Acinetobacter, Klebsiella, fungal, and other bacterial species, urine and blood cultures were categorized into bacterial and fungal microorganism growth. Reports of mixed urine cultures were omitted from the analysis. In this respect, no significant differences between recipients and non-recipients of tocilizumab were observed

Table 1. Sensitivity and resistance patterns of microorganisms detected in positive cultures of ICU-admitted COVID-19 patients receiving tocilizumab.

Microorganism	Antimicrobial agent	Resistance patterns N (%)		
		Sensitive	Intermediate	Resistant
<i>Escherichia coli</i> (N=4)	Ciprofloxacin	0	0	4 (100)
	Gentamicin	1 (25)	0	3 (75)
	Amikacin	3 (75)	1 (25)	0
	Sulfamethoxazole/Trimethoprim	-	-	-
	Cefixime	-	-	-
	Cefepime	3 (75)	0	1 (25)
	Ceftriaxone	1	0	3 (75)
	Cephalothin		0	4 (100)
	Nitrofurantoin	1 (25)	0	3 (75)
	Ampicillin/Sulbactam	0	2 (50)	2 (50)
	Imipenem	0	1 (25)	3 (75)
	Colistin	4 (100)	0	0
	<i>Klebsiella</i> spp. (N=5)	Ciprofloxacin	2 (40)	2 (40)
Gentamicin		5 (100)	0	0
Amikacin		5 (100)	0	0
Sulfamethoxazole/Trimethoprim		-	-	-
Cefixime		-	-	-
Cefepime		4 (80)	0	0
Ceftriaxone		2 (40)	0	3 (60)
Ampicillin/Sulbactam		2 (40)	0	2 (40)
Imipenem		4 (100)	0	1 (20)
Colistin		4 (80)	0	0
<i>P. aeruginosa</i> (N=2)		Ciprofloxacin	1 (50)	0
	Gentamicin	1 (50)	0	1 (50)
	Amikacin	0	1 (50)	1 (50)
	Sulfamethoxazole/Trimethoprim	-	-	-
	Cefixime	0	0	2 (100)
	Ceftriaxone	0	0	2 (100)
	Ampicillin/Sulbactam	0	0	2 (100)
	Imipenem	0	1 (50)	1 (50)
	Colistin	2 (100)	0	0

Continued Table 1.

<i>Acinetobacter</i> spp. (N=12)	Ciprofloxacin	0	2 (16.7)	10 (83.3)
	Gentamicin	2 (16.7)	4 (33.3)	6 (50)
	Amikacin	2 (16.7)	3 (25)	7 (58.3)
	Sulfamethoxazole/Trimethoprim	-	-	-
	Cefixime	-	-	-
	Cefepime	6 (50)	2 (16.7)	2 (16.7)
	Ceftriaxone	1 (8.3)	0	8 (66.7)
	Ampicillin/Sulbactam	0	1 (8.3)	5 (41.7)
	Imipenem	4 (33.3)	0	8 (66.7)
	Colistin	10 (83.3)	1 (8.3)	1 (8.3)
	<i>Streptococcus</i> spp. (N=1)	Ciprofloxacin	1 (100)	0
Gentamicin		0	0	1 (100)
Amikacin		0	0	1 (100)
Sulfamethoxazole/Trimethoprim		1 (100)	0	0
Cephalexin		0	0	1 (100)
Ceftriaxone		1 (100)	0	0
Imipenem		-	-	-
Nitrofurantoin		-	-	-
Erythromycin		1 (100)	0	0
Clindamycin		-	-	-
Vancomycin		1 (100)	0	0
<i>Staphylococcus aureus</i> (N=10)	Ciprofloxacin	1 (10)	-	5 (50)
	Gentamicin	4 (40)	0	0
	Amikacin	3 (30)	0	2 (20)
	Sulfamethoxazole/Trimethoprim	1(10)	0	3 (30)
	Cephalexin	-	-	-
	Cephalothin	1 (10)	1 (10)	1 (10)
	Cefazoline	3 (30)	0	5 (50)
	Ceftriaxone	2 (20)	0	0
	Imipenem	1(10)	0	0
	Nitrofurantoin	0	2 (20)	0
	Erythromycin	-	-	-
	Clindamycin	5 (50)	1 (10)	4 (40)
	Rifampin	6 (60)	1 (10)	0
	Vancomycin	7 (70)	1 (10)	2 (20)

Continued Table 1.

VRE (N=1)	Ciprofloxacin	0	0	1 (100)
	Gentamicin	1 (100)	0	0
	Amikacin	1 (100)	0	0
	Sulfamethoxazole/Trimethoprim	-	-	-
	Cephalexin	-	-	-
	Cephalothin	-	-	-
	Cefazoline	-	-	-
	Ceftriaxone	0	0	1 (100)
	Imipenem	1 (100)	0	0
	Nitrofurantoin	-	-	-
	Erythromycin	-	-	-
	Clindamycin	0	1 (100)	0
	Rifampin	0	1 (100)	0
	Vancomycin	0	0	1 (100)
	Ampicillin	0	0	1 (100)

Spp.: Species VRE: Vancomycin Resistant Enterococcus

regarding the microorganisms responsible for positive sputum culture results ($P=0.353$), urine culture results ($P=0.990$), and blood culture results ($P=1.000$) (Table 2).

4. Discussion

This study was designed with a retrospective methodology to report the patterns of microorganism growth in culture-positive secondary

infections following the use of tocilizumab in patients with severe COVID-19 infection admitted to the ICU of a teaching hospital in Shiraz, Iran. Although studies on the rate of secondary infection following treatment with tocilizumab are plenty, few studies have reported details regarding patterns of microorganism growth. Notably, conflicting results have been reported regarding the increased risk of secondary infections following the use of

Table 2. Comparison of microorganisms detected in cultures amongst patients with severe COVID-19 who received (case group) and did not receive (control group) tocilizumab.

Variable	Total	Receiving Tocilizumab		P value ²
		Yes	No	
Sputum culture microorganism				
Acinetobacter	29 (40.3)	10 (31.3)	19 (47.5)	0.353
Klebsiella	19 (12.5)	5 (15.6)	4 (10.0)	
Fungal	23 (31.9)	10 (31.3)	13 (32.5)	
Other bacteria	11 (15.3)	7 (21.9)	4 (10.0)	
Urine culture microorganism				
Bacterial	15 (24.2)	6 (24.0)	9 (24.3)	0.990
Fungal	40 (64.5)	16 (64.0)	24 (63.9)	
Blood culture microorganism				
Bacterial	10 (66.7)	7 (70.0)	3 (60.0)	1.000
Fungal	5 (33.3)	3 (30.0)	2 (40.0)	

¹ Count (%)
² Pearson's Chi-square test

tocilizumab in COVID-19 patients. Retrospective studies have predominantly suggested an association between tocilizumab and the occurrence of new infections, while most randomized controlled trials (RCTs) have provided insignificant or inconclusive results in this matter (19, 20). Minihan *et al.* reported that 63.4% of patients who received tocilizumab had a significant bacterial or fungal infection compared to 39.3% of those who did not, which was statistically higher among tocilizumab receivers (21). Moreover, Moreno-Torres *et al.* found that the occurrence of bacterial infections in hospitalized COVID-19 patients was positively correlated with receiving steroids and tocilizumab (OR = 3.29 [95% CI: 2.27, 4.76]) (22). The rate of secondary infection was high in this study compared to similar retrospective reports (14, 23, 24). This may have been due to the ICU setting of the study, more complicated health state of this study's patients that were admitted to the ICU, their longer ICU-stay, the dose of tocilizumab administered, co-administration of high dose glucocorticoids, poor practice of preventive measures for infection control that must be maintained in an ICU such as hand hygiene and many other issues that none were the aim of this study and unfortunately cannot be specifically discussed. Other reports have also confirmed the role of critical illness and ICU admission in increasing the risk of infection after tocilizumab therapy compared to non-ICU admitted patients (23).

We found that *Acinetobacter*, *Candida* species, and *Klebsiella* were the most common microorganisms detected in sputum cultures; *Candida* species and *E. coli* were the most frequent pathogens detected in urine cultures; and MRSA and *Acinetobacter* were the most prevalent microorganisms detected in blood cultures among tocilizumab recipients. Parallel to our study results, gram-negative bacteria and fungal infections have been shown to be the most common microorganisms detected as the causes of secondary infection among hospitalized COVID-19 patients treated with tocilizumab in another report that focuses on details of microorganism growth (14). In addition, Rana *et al.* showed that the gram-negative bacteria were the most common (75.5%) secondary infections detected in the culture of 90 (22.5%, out of 400) ICU-admitted COVID-19 patients who received tocilizumab, with *Pseudomonas* and *Ac-*

netobacter being the predominant strains. Contrary to the high rate of Gram-positive blood culture results in our study, Gram-positive infections were less common in the mentioned study, with *Enterococcus* and MRSA being the major strains (25). Serious infections such as infective endocarditis caused by MRSA following tocilizumab and corticosteroid use in COVID-19 patients have been reported in the literature (26). The setting of this study may play an important role in the MRSA-positive cultures reported. Placement of intravenous catheters, mechanical ventilation of patients, length of ICU admission and patient-specific risk factors including their past medical history of diabetes or even high blood glucose levels following administration of long-term glucocorticoids may be responsible for the gram-positive blood culture results (27). Less common cases of secondary infection among tocilizumab recipients has also been reported, including *Serratia marcescens*, and *Enterococcus faecalis* (28). Top five microorganisms reported in a similar study were also the same as results of our study, indicating *E. coli*, *Pseudomonas*, *Acinetobacter*, *Klebsiella*, and *S. aureus* as the most common organisms reported in the tocilizumab receivers' positive cultures (23). The study taking place in Africa and considering the probable poor facilities in the pandemic outbreak, similar to our setting, may be a comparable feature playing its part in the development of the harmful and resistant microorganisms reported. It must be mentioned that although the development of hazardous microorganisms is being associated to tocilizumab use, it was evident that no difference was observed in terms of positive culture results between receivers and non-receivers of tocilizumab. As results indicate, patterns of microorganism growth were comparable between the two groups of the study and this may be due to the critical status of both groups of patients and also their already immunosuppressed condition following the administration of glucocorticoids in both groups. Therefore, although the higher growth rates of microorganisms can be related to tocilizumab use, growth patterns may be independent of tocilizumab therapy. It should be noted that a noticeable portion of bacterial causes of secondary infection in our study, were only sensitive to the last available antibiotic choices, including colistin, vancomycin and imipenem, which raises safety

concerns against the management of patients who receive tocilizumab and other immunosuppressant agents putting patients at risk of infection. This issue may once again be attributed to the high loads of patient turnover in the ICU at the time of the study, poor application of preventive measures for reducing rate of infection in such settings, and the uncontrolled misuse of antibiotics in the community that leads to resistance patterns.

This study has its limitations. Although the number of patients included in the study was sufficient, missed data and poor documentation lead to patient loss in studies with a retrospective nature as was encountered in the data collection of this study. Also, the number of positive culture reports may be less than the actual positive cultures expected which may be due to false negative reports following a prior history of antibiotic use before sample collection. Similarly, some of the positive cultures may be due to colonization of bacteria rather than true infections and unfortu-

nately, the means for discriminating the two was not available in this study. Regrettably, the clinical outcome of patients according to their culture results has not been reported since it was not primarily considered as the aim of the study and relevant data was not collected during data gathering.

5. Conclusion

A high rate of secondary infection was observed in severely infected COVID-19 patients admitted to the ICU following the use of tocilizumab. Patterns of infection indicate the presence of nosocomial microorganisms with multi-drug resistant potentials that may propose poor outcomes for hospitalized ICU-admitted patients with extents of immunosuppression following the use of anti-inflammatory medications regardless of tocilizumab use.

Conflict of Interest

The authors declare no conflict of interest.

References

1. Alimohamadi Y, Sepandi M, Taghdir M, Hosamirudsari H. Determine the most common clinical symptoms in COVID-19 patients: a systematic review and meta-analysis. *J Prev Med Hyg.* 2020 Oct 6;61(3):E304-E312. doi: 10.15167/2421-4248/jpmh2020.61.3.1530.
2. Perisetti A, Goyal H, Gajendran M, Boregowda U, Mann R, Sharma N. Prevalence, Mechanisms, and Implications of Gastrointestinal Symptoms in COVID-19. *Front Med (Lausanne).* 2020 Oct 30;7:588711. doi: 10.3389/fmed.2020.588711.
3. Ahmad I, Rathore FA. Neurological manifestations and complications of COVID-19: A literature review. *J Clin Neurosci.* 2020 Jul;77:8-12. doi: 10.1016/j.jocn.2020.05.017.
4. Mirmoenei S, Azari Jafari A, Hashemi SZ, Angouraj Taghavi E, Azani A, Ghasrsaz H, Angouraj Taghavi A, Niksima SH, Rashidi S, Kazemi E, Sheibani H, Naghibi Irvani SS, Dalvand S. Cardiovascular manifestations in COVID-19 patients: A systematic review and meta-analysis. *J Cardiovasc Thorac Res.* 2021;13(3):181-189. doi: 10.34172/jcvtr.2021.30.
5. Abidi E, El Nekidy WS, Alefishat E, Rahman N, Petroianu GA, El-Lababidi R, Mallat J. Tocilizumab and COVID-19: Timing of Administration and Efficacy. *Front Pharmacol.* 2022 Feb 18;13:825749. doi: 10.3389/fphar.2022.825749.
6. The Novel Coronavirus Pneumonia Emergency Response Epidemiology Team. The Epidemiological Characteristics of an Outbreak of 2019 Novel Coronavirus Diseases (COVID-19) - China, 2020. *China CDC Wkly.* 2020 Feb 21;2(8):113-122.
7. Kordzadeh-Kermani E, Khalili H, Karimzadeh I. Pathogenesis, clinical manifestations and complications of coronavirus disease 2019 (COVID-19). *Future Microbiol.* 2020 Sep;15:1287-1305. doi: 10.2217/fmb-2020-0110.
8. Huang C, Wang Y, Li X, Ren L, Zhao J, Hu Y, et al. Clinical features of patients infected with 2019 novel coronavirus in Wuhan, China. *Lancet.* 2020 Feb 15;395(10223):497-506. doi: 10.1016/S0140-6736(20)30183-5.
9. Moore JB, June CH. Cytokine release syndrome in severe COVID-19. *Science.* 2020 May 1;368(6490):473-474. doi: 10.1126/science.abb8925. Epub 2020 Apr 17. PMID: 32303591.
10. Cortegiani A, Ippolito M, Greco M, Granone V, Protti A, Gregoretti C, et al. Rationale and evidence on the use of tocilizumab in COVID-19: a systematic review. *Pulmonology.* 2021 Jan-Feb;27(1):52-66. doi: 10.1016/j.pulmoe.2020.07.003.
11. Stone JH, Frigault MJ, Serling-Boyd NJ,

Fernandes AD, Harvey L, Foulkes AS, et al. Efficacy of Tocilizumab in Patients Hospitalized with COVID-19. *N Engl J Med.* 2020 Dec 10;383(24):2333-2344. doi: 10.1056/NEJMoa2028836.

12. Fu B, Xu X, Wei H. Why tocilizumab could be an effective treatment for severe COVID-19? *J Transl Med.* 2020 Apr 14;18(1):164. doi: 10.1186/s12967-020-02339-3. PMID: 32290839; PMCID: PMC7154566.

13. Okuda Y. Review of tocilizumab in the treatment of rheumatoid arthritis. *Biologics.* 2008 Mar;2(1):75-82. doi: 10.2147/btt.s1828. PMID: 19707430; PMCID: PMC2727785.

14. Sandhu G, Piraino ST, Piticaru J. Secondary Infection Risk in Patients With Severe COVID-19 Pneumonia Treated With Tocilizumab. *Am J Ther.* 2022 May-Jun 01;29(3):e275-e278. doi: 10.1097/MJT.0000000000001487. Epub 2022 Mar 4. PMID: 35249968.

15. Lang VR, Englbrecht M, Rech J, Nüsslein H, Manger K, Schuch F, et al. Risk of infections in rheumatoid arthritis patients treated with tocilizumab. *Rheumatology (Oxford).* 2012 May;51(5):852-7. doi: 10.1093/rheumatology/ker223.

16. Viswanatha GL, Anjana Male CKVLSN, Shylaja H. Efficacy and safety of tocilizumab in the management of COVID-19: a systematic review and meta-analysis of observational studies. *Clin Exp Rheumatol.* 2022 Mar;40(3):634-646. doi: 10.55563/clinexprheumatol/4dg0or.

17. Karimzadeh I, Mirzaee M, Sadeghimanesh N, Sagheb MM. Antimicrobial resistance pattern of Gram-positive bacteria during three consecutive years at the nephrology ward of a tertiary referral hospital in Shiraz, Southwest Iran. *J Res Pharm Pract.* 2016 Oct-Dec;5(4):238-247. doi: 10.4103/2279-042X.192460.

18. Karimzadeh I, Sadeghimanesh N, Mirzaee M, Sagheb MM. Evaluating the resistance pattern of gram-negative bacteria during three years at the nephrology ward of a referral hospital in southwest of Iran. *J Nephropathol.* 2017 Jul;6(3):210-219. doi: 10.15171/jnp.2017.35.

19. Ignatius EH, Wang K, Karaba A, Robinson M, Avery RK, Blair P, et al. Tocilizumab for the Treatment of COVID-19 Among Hospitalized Patients: A Matched Retrospective Cohort Analysis. *Open Forum Infect Dis.* 2020 Dec 28;8(1):ofaa598. doi: 10.1093/ofid/ofaa598.

20. Moore JL, Stroever SJ, Rondain PE, Scat-

ena RN. Incidence of Secondary Bacterial Infections Following Utilization of Tocilizumab for the Treatment of COVID-19 - A Matched Retrospective Cohort Study. *J Glob Infect Dis.* 2021 Mar 22;13(2):67-71. doi: 10.4103/jgid.jgid_358_20.

21. Minihan B, McAuliffe E, Powell J, Wong SL, Wilkie K, Murphy C, et al. Association between tocilizumab treatment of hyperinflammatory patients with COVID-19 in a critical care setting and elevated incidence of hospital-acquired bacterial and invasive fungal infections. *J Hosp Infect.* 2022 Aug;126:29-36. doi: 10.1016/j.jhin.2022.04.007.

22. Moreno-Torres V, de Mendoza C, de la Fuente S, Sánchez E, Martínez-Urbistondo M, Herráiz J, et al. Bacterial infections in patients hospitalized with COVID-19. *Intern Emerg Med.* 2022 Mar;17(2):431-438. doi: 10.1007/s11739-021-02824-7.

23. Shah R, Shah J, Gohil J, Revathi G, Surani S. Secondary Infections in Patients with COVID-19 Pneumonia Treated with Tocilizumab Compared to Those Not Treated with Tocilizumab: A Retrospective Study at a Tertiary Hospital in Kenya. *Int J Gen Med.* 2022 Mar 3;15:2415-2425. doi: 10.2147/IJGM.S356547.

24. Guaraldi G, Meschiari M, Cozzi-Lepri A, Milic J, Tonelli R, Menozzi M, et al. Tocilizumab in patients with severe COVID-19: a retrospective cohort study. *Lancet Rheumatol.* 2020 Aug;2(8):e474-e484.

25. Rana MA, Chachar AZK, Zartash S, Siddiqui MH, Naqvi SMA, Javed M, et al. Post tocilizumab secondary infections in COVID-19 patients—are we doing enough. *Pakistan J Med Health Sci.* 2021;15:2023-6.

26. Barahimi E, Defae S, Shokraei R, Sheybani-Arani M, Salimi Asl A, Ghaem HM. Bacterial endocarditis following COVID-19 infection: two case reports. *J Med Case Rep.* 2023 Jun 16;17(1):274. doi: 10.1186/s13256-023-03970-6.

27. Singh N, Puri S, Anshul, Kumar S, Pahuja H, Kalia R, et al. Risk Factors and Outcome Analysis of Gram-Positive Bacteremia in Critically Ill Patients. *Cureus.* 2023 Mar 23;15(3):e36585.

28. Hill JA, Menon MP, Dhanireddy S, Wurfel MM, Green M, Jain R, et al. Tocilizumab in hospitalized patients with COVID-19: Clinical outcomes, inflammatory marker kinetics, and safety. *J Med Virol.* 2021 Apr;93(4):2270-2280. doi: 10.1002/jmv.26674.