

## Effect of Topical Phenytoin in Treatment of Corneal Epithelial Defects in Rabbits

Masoomeh Eghtedari<sup>1</sup>, Vahid Beigi<sup>1,\*</sup>, Mohammad Reza Soltani<sup>1</sup>

<sup>1</sup> Poostchi ophthalmology research center, School of Medicine, Shiraz University of Medical Sciences, Shiraz, Iran.

### Abstract

Re-epithelialization of corneal epithelium is a major problem in delayed corneal wound healing. Phenytoin has been used topically for different types of cutaneous wounds and ulcers. The aim of this study was to assess the efficacy of topical phenytoin eye drop and ointment 1% and on the induced sterile corneal epithelial ulcers in rabbit eyes. Fifty eyes from 30 rabbits were evaluated for induction of corneal epithelial ulcer in this study. The right corneas of all rabbits underwent total epithelial debridement. Randomization was made. Odd labeled eyes as control group received artificial tear and even labeled eyes as case group received phenytoin 1% eye drop. Slit lamp examination was performed on day 1, 3, 5, and 7. After healing of the right eyes, the same procedure was performed on 20 corneas of the left eyes. In the left eyes, phenytoin ointment 1% was used instead of phenytoin eye drop 1%. There was no statistically significant difference between corneas that received phenytoin 1% eye drop (n=15) and control group that received placebo (n=15) in the right eyes ( $P>0.05$ ). Moreover, difference between corneas received phenytoin ointment 1% (n=10) or placebo (n=10) in the left eyes ( $P>0.05$ ) was not significant. The results of this study did not show positive effect of phenytoin on acceleration of healing process in rabbit's corneal ulcer. Further study in non-healing corneal ulcers is required to show phenytoin efficacy. Phenytoin ointment in comparison to phenytoin drop was better for ophthalmic usage. Application of topical phenytoin 1% in corneal ulcer in rabbits was safe and no severe side effect was observed.

**Keywords:** Corneal ulcer, Diphenylhydantion sodium, Phenytoin, Wound healing.

### 1. Introduction

Re-epithelialization of the cornea is a major problem in delayed corneal wound healing. Corneal wound is caused by a variety of etiologies such as infections, trauma, foreign bodies, and recurrent corneal erosion syndrome. Sometimes, despite total eradication of the infective agents, there is delayed epithelialization, making the cornea more prone to re-infection, especially the bacterial infection. Delay in corneal epithelialization causes eye pain, photophobia, lacrimation, and change in visual acuity. There are a number of ways to deal

this major problem such as use of lubrication and soft bandage lenses, anterior stromal micropuncture, conjunctival flaps, or even keratoplasties (1). Many recent research activities have been directed towards attempts to facilitate re-epithelialization using chemical stimulation.

Diphenylhydantion sodium (phenytoin) is a classical antiepileptic drug. Gingival overgrowth is a common side effect observed in the majority of patients treated with phenytoin (2). In 1958, a clinical study showed the acceleration of gingival wound healing with phenytoin sodium as compared to controls (3). Positive effect of topical phenytoin in the healing of many chronic cutaneous ulcers such as bed sores, diabetic ulcers, burns, war wound, and trophic ulcers in clinical

*Corresponding Author:* Vahid Beigi, Poostchi ophthalmology research center, School of Medicine, Shiraz University of Medical Sciences, Shiraz, Iran  
Email: v.beigi66@gmail.com

and experimental studies have been reported in many studies (4-8). Moreover, in an animal study, the positive effect of phenytoin eye drop 1% on acceleration in the healing process of alkali burn-induced corneal wound was reported (9). The possible mechanisms of action of phenytoin in wound healing are complex. A study identified gene expression profile changes in human dermal fibroblasts caused by phenytoin. Gene expression profile analysis revealed that the expression of the main growth factors and their receptors, which are involved in wound healing, were increased (10). It seems that PHT (phenytoin) can stimulate fibroblast proliferation, collagen production, growth factor activation, and reduction in collagenase activity (11). To our knowledge, there have been no studies on human eyes thus far. In this study, the effect of topical phenytoin eye drop and ointment 1% on the induced corneal epithelial ulcer healing in rabbit was evaluated.

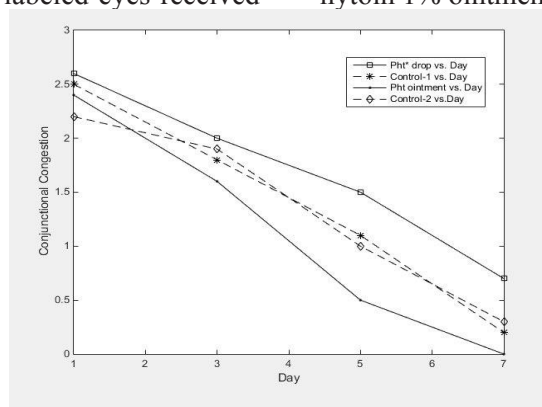
## 2. Material

In a randomized controlled experimental study, 50 eyes of 30 rabbits (white, New Zealand, weighing between 2-3 kg) were included in the study. All rabbits were placed under generalized anesthesia with intramuscular injection of ketamin 35 mg/kg and xylazine 5 mg/kg. After the use of 95% alcohol for 40 seconds, the total corneal epithelia of rabbits' right eye were removed using mechanical scraping. Randomization was made and each rabbit received either an odd or even numbers. All the procedures were performed by same surgeon and randomization was made by an assistant. Odd labeled eyes and even labeled eyes received

artificial tear and phenytoin 1% for 4 times a day, respectively. Both eye drop bottles with similar containers were labeled as odd or even. All eyes received one drop of chloramphenicol 1% twice a day for prevention of infection. Animal laboratory technicians were advised to shake the bottles well before use. Slit-lamp examination was performed on day 1, 3, 5, and 7 or more if indicated. During each session, the percentages of epithelial defect conjunctival congestion grades ( $0^+$ ,  $1^+$ ,  $2^+$ ,  $3^+$ ) and any other abnormal finding after fluorescein staining of the cornea were measured by the examiner that was unaware of the subjects label. After complete corneal epithelium healing was achieved in all right eyes, researchers changed to topical phenytoin ointment 1% to continue the study on the left eyes of the same rabbits. Twenty left eyes were randomized to receive drug or placebo after epithelial scraping by the same method in right eyes. 1% Phenytoin topical cream or artificial eye drop was applied to the odd and even labeled left eyes, respectively. Slit-lamp examination and masking method were used in the same way as in the right eye. All data were analyzed using SPSS software version 11.5.0.

## 3. Results

In this experimental study, 50 eyes (30 right eyes, 20 left eyes) of 30 rabbits were included. The first observation was conducted on right eyes of the rabbits ( $n=30$ ). Fifteen eyes received phenytoin 1% drop and fifteen eyes received placebo. Second observation was conducted on left eyes of the rabbits ( $n=20$ ). Ten eyes received phenytoin 1% ointment and 10 eyes received placebo.



**Figure 1.** Conjunctival injection grading ( $0^+$ ,  $1^+$ ,  $2^+$ ,  $3^+$ ) according to slit lamp examination. \*Pht, phenytoin.

**Table 1.** Percentage of corneal epithelial defect after prescription of phenytoin.

Day	Percentage of mean epithelial defect area $\pm$ SD			
	Phenytoin 1% drop(n=15)	Control(n=15)	Phenytoin 1% ointment (n=10)	Control(n=10)
1	79.9% $\pm$ 14.1% ( $P>0.05$ )	85.3% $\pm$ 16.1%	71.0% $\pm$ 13.1% ( $P>0.05$ )	72.5% $\pm$ 7.9%
3	30.8% $\pm$ 20.3% ( $P>0.05$ )	35.7% $\pm$ 21.2%	3.2% $\pm$ 5.5% ( $P>0.05$ )	8.1% $\pm$ 4.8%
5	17.0% $\pm$ 19.3% ( $P>0.05$ )	15.5% $\pm$ 21.5%	0.5% $\pm$ 1.1% ( $P>0.05$ )	2.8% $\pm$ 3.01%
7	2.5% $\pm$ 4.5 ( $P>0.05$ )	7.0% $\pm$ 13.6%	0.00% $\pm$ 0.00% ( $P>0.05$ )	0.00% $\pm$ 0.00%

Mean  $\pm$  standard deviation of epithelial defect area percentage and grade of conjunctival congestion at day 1, 3, 5, and 7 in each group is shown in Table 1 and Figure 1, respectively. Statistical analysis was performed with t-test. There was no statistically significant difference between eyes received phenytoin 1% eye drop or ointment and eyes received placebo in both observations.

#### 4. Discussion

The capacity of phenytoin as a topical agent to accelerate ulcer healing was reported from 1958. Since then, it has been used topically and orally for different kinds of wounds and ulcers such as decubitus, trophic, diabetic, venous stasis, oral ulcers, gastrointestinal fistulas, war wounds, and burns (4-8, 12). Results of systemic review analysis shows positive effect of phenytoin in various wound healing (13). Phenytoin is not approved by food and drug administration (FDA), but topical and oral uses of phenytoin for wound healing are within the guideline set forth by the FDA (14). Topical application of phenytoin for corneal wound healing is preferable due to the nature of the cornea and probable side effect of oral form. Topical phenytoin as a drug for ophthalmic application is not available. Phenytoin 1% ophthalmic drop and ointment can be prepared by adding its injectable form to artificial tear or by adding its powder to a simple ophthalmic ointment, respectively. Injectable phenytoin has a high pH (about 12) and should not be used topically because it can make damage (14).

In this experiment, we did not observe any short term serious side effects in rabbit eyes, as well as previous reports of other topical phenytoin applications for acceleration of wound healing (15). As shown in Figure 1, conjunctival conges-

tion was less in the eyes of rabbits received phenytoin ointment in comparison to those received phenytoin drops or control groups, and congestion in phenytoin drop group was slightly higher than the other groups. Reduction in conjunctival congestion by phenytoin ointment may be due to its anti-inflammatory effect. Biopsies of phenytoin treated open wounds showed decreased polymorphonuclear and eosinophil cell infiltration (11, 16, 17). We found that phenytoin ointment is a better route for its delivery to the eye, because phenytoin drop was irrigative for rabbit eyes and induced more congestion. Increased congestion by phenytoin drop may be due to its high PH.

Normal healing process in injured corneal epithelial tissue is evident within one h after injury by enlargement and flattening of adjacent epithelial cells. The process of sliding is so rapid that a cornea denuded of its entire epithelium can be recovered within four to seven days (18). Normal healing process was observed in all corneas of case and control groups and no phenytoin induced acceleration in healing process was found. This may be due to rapid corneal epithelial renewal. Further studies on chronic non-healing corneal ulcers are required to confirm positive effect of phenytoin. Positive effect of phenytoin after induced alkali burns in rabbit corneas was observed in a previous study (9). In a recent study, all electronic data bases relevant to randomized clinical trial (RCT) about topical phenytoin for treating pressure ulcers were evaluated. All participants of RCTs had grade I or grade II ulcers; no participants had grade III or IV ulcers. The result of this study shows that it is uncertain whether topical phenytoin improves ulcer healing for patients with grade I and II pressure ulcers (15).

Our study was designed for induced ster-

ile corneal ulcers, which was the study limitation. Regarding the anti-infective effect of phenytoin (7, 17), it may be suitable adjunctive treatment in infective corneal ulcers. A study designed for infective corneal ulcer may better show phenytoin efficacy. According to our observation, application of phenytoin for accelerating normal healing process of corneal ulcers is not an

---

## 5. References

1. Ramamurthi S, Rahman MQ, Dutton GN, Ramaesh K. Pathogenesis, clinical features and management of recurrent corneal erosions. *Eye (Lond)*. 2006;20:635-44.
2. Kimball OP, Horan TN. The use of Dilantin in the treatment of epilepsy. *Ann Int Med*. 1939;13:787e93.
3. SHAPIRO M. Acceleration of gingival wound healing in non-epileptic patients receiving diphenylhydantoin sodium (dilantin, epanutin). *Exp Med Surg*. 1958;16:41-53.
4. Inchingolo F1, Vermesan D, Inchingolo AD, Malcangi G, Santacroce L, Scacco S, Benagiano V, et. al. Bedsores successfully treated with topical phenytoin. *Acta Biomed*. 2017;88:45-8.
5. Patil V, Patil R, Kariholu PL, Patil LS, Shahapur P. Topical Phenytoin Application in Grade I and II Diabetic Foot Ulcers: A Prospective Study. *J Clin Diagn Res*. 2013;7:2238-40.
6. Sayar H, Gergerlioglu N, Seringec N, Ozturk P, Bulbuloglu E, Karabay G. Comparison of efficacy of topical phenytoin with hypericin in second-degree burn wound healing: an experimental study in rats. *Med Sci Monit Basic Res*. 2014;20:36-46.
7. Modaghegh S, Salehian B, Tavassoli M, Djamshidi A, Rezai AS. Use of phenytoin in healing of war and non-war wounds. A pilot study of 25 cases. *Int J Dermatol*. 1989;28:347-50.
8. Bhatia A, Nanda S, Gupta U, Gupta S, Reddy BS. Topical phenytoin suspension and normal saline in the treatment of leprosy trophic ulcers: a randomized, double-blind, comparative study. *J Dermatolog Treat*. 2004 ;15:321-7.
9. Mohammad Naeim Aminifard, Hamid Reza Barkhordari Yazdi, Shabnam Pahlavanzadeh, Evaluation of Topical Phenytoin Eye Drop

indictable prescription.

## Acknowledgements

This work has been supported by a grant from Shiraz University of Medical Sciences.

## Conflict of Interest

None declared.

1% Therapeutic Effects on Corneal Alkali Burns in Rabbit Model. *Iranian Journal of Ophthalmology*. 2012;24:33-8.

10. Swamy SM, Tan P, Zhu YZ, Lu J, Achuth HN, Moochhala S. Role of phenytoin in wound healing: microarray analysis of early transcriptional responses in human dermal fibroblasts. *Biochem Biophys Res Commun*. 2004;314:661-6.

11. Bhatia A, Prakash S. Topical phenytoin for wound healing. *Dermatol Online J*. 2004;10:5. Review.

12. Jaber S, Rihiy Z, Joseph R, Al-Khayat M. Does phenytoin improve the healing of gastrointestinal fistulas? *Case Rep Gastroenterol*. 2011;5:52-5.

13. Shaw J, Hughes CM, Lagan KM, Bell PM. The clinical effect of topical phenytoin on wound healing: a systematic review. *Br J Dermatol*. 2007;157:997-1004.

14. Anstead GM, Hart LM, Sunahara JF, Liter ME. Phenytoin in wound healing. *Ann Pharmacother*. 1996;30:768-75.

15. Hao XY, Li HL, Su H, Cai H, Guo TK, Liu R, Jiang L, Shen YF. Topical phenytoin for treating pressure ulcers. *Cochrane Database Syst Rev*. 2017;2:CD008251.

16. Abdou AG, Abdelwahed Gaber M, Elnaidany NF, Elnagar A. Evaluation of the effect and mechanism of action of local phenytoin in treatment of vitiligo. *J Immunoassay Immunochem*. 2017;38:523-37.

17. Lodha SC, Lohiya ML, Vyas MC, Bhandari S, Goyal RR, Harsh MK. Role of phenytoin in healing of large abscess cavities. *Br J Surg*. 1991;78:105-8.

18. Lemp MA. Cornea and sclera. *Arch Ophthalmol*. 1974;92:158-70.