

Taurine Alleviates Brain Tissue Markers of Oxidative Stress in a Rat Model of Hepatic Encephalopathy

Akram Jamshidzadeh^{1,2}, Narges Abdoli³, Hossein Niknahad^{1,2}, Negar Azarpira⁴, Elnaz Mardani², Somayeh Mousavi², Mojgan Abasvali², Reza Heidari^{1,*}

¹Pharmaceutical Sciences Research Center, Shiraz University of Medical Sciences, Shiraz, Iran.

²Department of Pharmacology and Toxicology, School of Pharmacy, Shiraz University of Medical Sciences, Shiraz, Iran.

³Iran Food and Drug Administration (IFDA), Ministry of Health, Tehran, Iran.

⁴Transplant Research Center, Shiraz University of Medical Sciences, Shiraz, Iran.

Abstract

Hepatic encephalopathy (HE) is a serious clinical complication, which could lead to coma and death if not appropriately managed. There is agreement on the predominant role of ammonia in the etiology of HE. Brain is one of the most critical organs affected by ammonia. The critical role of oxidative stress and its consequences in the pathogenesis of ammonia-induced brain injury have been revealed before. On the other hand, there is no promising therapeutic option against ammonia neurotoxicity. Taurine is one of the most abundant amino acids in the human body. Several pharmacological roles including brain protecting properties have been attributed to this amino acid. The current study was designed to evaluate the role of taurine supplementation on HE-induced oxidative stress in the brain tissue. Animals received thioacetamide (400 mg/kg, i.p, for three consecutive days at 24-hr intervals) as a model of acute liver failure and hyperammonemia. Several serum biochemical parameters, in addition to plasma and brain ammonia level, were monitored. Moreover, markers of oxidative stress in the brain of hyperammonemic animals were assessed. It was found that plasma and brain ammonia was increased, and serum markers of liver injury were significantly elevated in the thioacetamide-treated group. On the other hand, an increase in markers of oxidative stress, including reactive oxygen formation, lipid peroxidation, glutathione depletion, and decreased tissue antioxidant capacity, was detected in the brain tissue of thioacetamide-treated animals. It was found that taurine treatment (250, 500, and 1000 mg/kg, i.p) alleviated brain tissue markers of oxidative stress and decreased serum biomarkers of liver injury. Furthermore, lower plasma and brain ammonia were detected in taurine-treated animals. These data suggest taurine as a potential protective agent with therapeutic capability against HE-associated central nervous system complications.

Keywords: Antioxidant; Amino acid; Brain injury; Hyperammonemia; Oxidative Stress.

1. Introduction

Hepatic encephalopathy (HE) is a serious clinical complication accompanied by acute or chronic liver injury (1). Although the precise

mechanisms of organ injury during HE is not known, there is agreement on the predominant role of ammonia in HE etiology (2). Ammonia is metabolized to urea by liver, which is finally excreted through the kidneys. On the other hand, damaged livers are unable to metabolize ammonia. Hence, this toxic chemical is elevated in the systemic cir-

Corresponding Author: Reza Heidari, Pharmaceutical Sciences Research Center, Shiraz University of Medical Sciences, Shiraz, Iran. Email: rezaheidari@hotmail.com; rheidari@sums.ac.ir.

ulation. The brain is an important target affected by ammonia (3, 4). Ammonia is a neurotoxin that mostly influences astrocytes as well as neurons in the central nervous system (CNS) (5, 6). It has been found that ammonia causes oxidative stress, brain edema, and inflammation, when its level is raised during HE (3). Consequently, brain normal function will be suppressed in patients with HE (3). Hyperammonemia also affects other tissues including liver, skeletal muscle, heart, and kidneys (7).

Increased reactive oxygen species (ROS) and oxidative stress are known to be implicated in the etiology of ammonia-induced neurotoxicity (5, 8). It has been found that ammonia is capable of generating free radicals and decreasing the antioxidant capacity of neurons and astrocytes (9-13). Decreased activity of various antioxidant enzymes (e.g superoxide dismutase, catalase, and glutathione peroxidase) has been documented in different experimental models or human cases of HE (9-13). On the other hand, increased lipid peroxidation and brain tissue glutathione depletion is an important feature of hyperammonemia and HE (9-13). Hence, targeting oxidative stress and its associated complications might represent a useful approach for managing HE-induced CNS injury.

Taurine (2-aminoethanesulfonic acid) is a non-protein amino acid abundantly found in the brain, heart, and muscle tissues (14). Several physiological and pharmacological properties are attributed to this amino acid (15). Taurine is an antioxidant, osmoregulator, membrane stabilizer, and probably a neurotransmitter (16-18). Bile acid conjugation is a well-known physiological process mediated by taurine in the liver (19). On the other hand, the protective effects of taurine against a wide range of xenobiotics were repeatedly proved (20-28). Taurine also was shown to have a profound effect on the CNS (29-33). It was demonstrated that taurine acts as an osmoregulator, protects neurons, prevents astrocytes swelling, and encounters oxidative stress in CNS (34-37). The neuroprotective properties of taurine were also revealed in several neurological disorders (38-41).

As mentioned, oxidative stress and its consequent events serve as key mechanisms involved in ammonia-induced brain injury. Hence, antioxi-

dant and protective agents might mitigate ammonia-induced central nervous system complications during HE episodes. The current investigation was designed to evaluate the effect of taurine treatment on the brain tissue oxidative stress markers in a rat model of acute liver failure and hyperammonemia.

2. Material and methods

2.1. Chemicals

Thioacetamide, fatty acid-free bovine serum albumin (BSA) fraction V, 4,2 hydroxyethyl, 1-piperazineethanesulfonic acid (HEPES), thiobarbituric acid (TBA), n-butanol, dithiobis-2nitrobenzoic acid (DTNB), glutathione (GSH), 2',7' dichlorofluorescein diacetate (DCFH-DA), malondialdehyde (MDA), 2-aminoethanesulfonic acid (Taurine), sucrose, KCl, dithiothreitol, Coomassie brilliant blue, hydrochloric acid (HCl), ethylenediaminetetraacetic acid (EDTA), and ethylene glycol-bis (2-aminoethylether)-N,N,N',N'-tetraacetic acid (EGTA) were purchased from Sigma Chemical Co. (St. Louis, MO, USA). Trichloroacetic acid (TCA), potassium bicarbonate, ammonium chloride, and hydroxymethyl aminomethane hydrochloride (Tris-HCl) were purchased from Merck (Darmstadt, Germany). All salts for preparing buffer solutions were of analytical grade and obtained from Merck (Darmstadt, Germany).

2.2. Animals

Male Sprague-Dawley rats (200-250 g) were obtained from Animal Breeding Center of Shiraz University of Medical Sciences, Shiraz, Iran. Rats were housed in cages on wood-chip bedding at a temperature of 23 ± 1 °C. Animals had free access to tap water and a standard chow diet (Behparvar[®], Tehran, Iran). Animals received humane care and use and were handled according to the animal handling protocol approved by a local ethics committee at Shiraz University of Medical Sciences (#95-01-36-12042).

2.3. Animal model of acute liver failure

Thioacetamide is extensively used as a model of acute liver failure (42). For this purpose, three consecutive intraperitoneal (i.p) injections of thioacetamide (400 mg/kg) to rats at 24-hr intervals was used (43). Taurine (250, 500, and 1000

mg/kg, i.p) was administered for three consecutive days, two hr after each dose of thioacetamide. The treatments were as follow (n=48; 8 rats/group): 1) Control (Vehicle-treated); 2) Thioacetamide; 3) Thioacetamide + Taurine 250 mg/kg; 4) Thioacetamide + Taurine 500 mg/kg; 5) Thioacetamide + Taurine 1000 mg/kg; and 6) Taurine 1000 mg/kg.

On the fourth day (24 hr after the last dose of thioacetamide), animals were anesthetized (thiopental, 80 mg/kg, i.p) and their blood, liver, and brain samples were collected. Supportive therapy by administering 5% dextrose (2.5 ml/kg body weight, S.C) containing 0.45% sodium chloride and 0.2% potassium chloride, was given to avoid weight loss, hypoglycemia, and renal failure in thioacetamide-treated animals (43). Control animals (Vehicle-treated) received normal saline as the thioacetamide solvent. The sole TA (1000 mg/kg, i.p) was administered to ensure its safety (44).

2.4. Blood biochemistry and tissue histopathology

A MindrayBS-200[®] auto analyzer and standard kits were used to measure serum alanine aminotransferase (ALT), aspartate aminotransferase (AST), and lactate dehydrogenase (LDH) (27). Plasma ammonia was measured with standard kits based on the absorbance photometry method of phenate-hypochlorate reaction (45). To determine brain ammonia content, samples (100 mg) of the forebrain (cerebral cortex) were dissected, homogenized, and deproteinized in 3 mL of ice-cooled lysis solution (Trichloroacetic acid, 6%, w/v). After centrifugation (12000 g, 10 minutes, 4 °C), the supernatant was collected and neutralized with KHCO₃ (2 mol/l, pH=7). Afterward, brain ammonia content was measured using standard kits (45).

For histopathological evaluation, tissue samples were fixed in phosphate-buffered formalin solution (0.4% sodium phosphate monobasic, NaH₂PO₄, 0.64% sodium phosphate dibasic, Na₂HPO₄, and 10% formaldehyde in distilled water) (46, 47). Paraffin-embedded sections of liver were prepared and stained with haematoxylin and eosin (H&E) before light microscope viewing.

2.5. Reactive oxygen species formation in the brain tissue

Reactive oxygen species (ROS) formation in the brain was estimated by a previously described method (24, 48, 49). Briefly, brain tissue was homogenized in 5 ml of ice-cooled Tris-HCl buffer (40 mM, pH=7.4). Samples of the resulted tissue homogenate (100 µL) were mixed with Tris-HCl buffer (1 ml) and 2', 7' dichlorofluorescein diacetate (final concentration 10 µM). The mixture was incubated at 37 °C (15 min, in dark). Finally, the fluorescence intensity (FI) of the samples was assessed using a FLUOstar Omega[®] multifunctional microplate reader at λ excitation=485 nm and λ emission=525 nm (48, 50).

2.6. Brain tissue glutathione content

Tissue samples (100 mg) were homogenized in 4 ml of ice-cooled EDTA (20 mM; 4 °C). Then, 2.5 ml of the prepared homogenate were added to 1 ml of distilled water and 500 µl of trichloroacetic acid (50% w/v). Samples were mixed well and centrifuged (10,000 g, 4 °C, 25 min). Then, 2 ml of the supernatant was mixed with 4 ml of Tris-HCl buffer (pH=8.9; 4 °C), and 100 µl of DTNB (0.01 M in methanol) (51). Finally, the absorbance of the developed color was measured at λ=412 nm using an Ultrospec 2000[®]UV spectrophotometer (Pharmacia Biotech, Uppsala, Sweden) (49, 52).

2.7. Lipid peroxidation

As an index of lipid peroxidation, the thiobarbituric acid reactive substances (TBARS) test was used (52). The reaction mixture was consisted of 500 µl of tissue homogenate (10% w/v in KCl, 1.15%), 1 ml of thiobarbituric acid (0.375%, w/v), and 3 ml of phosphoric acid (1% w/v, pH=2). Samples were mixed well and heated (100 °C for 45 min). After the incubation period, the mixture was cooled, and then 2 ml of n-butanol was added. Samples were vigorously vortexed and centrifuged (10,000 g for 5 min). Finally, the absorbance of developed color in n-butanol phase was read at λ=532 nm using an Ultrospec 2000[®]UV spectrophotometer (Pharmacia Biotech, Uppsala, Sweden) (52, 53).

2.8. Ferric reducing antioxidant power (FRAP) of brain tissue

FRAP assay measures the formation of a blue colored Fe^{2+} -tripyridyltriazine compound from the colorless oxidized Fe^{3+} form by the action of electron-donating antioxidants (54). In the current study, the working FRAP reagent was prepared by mixing 10 volumes of acetate buffer (300 mmol/L, pH=3.6), with 1 volume of TPTZ (10 mmol/L in 40 mmol/L hydrochloric acid) and 1 volume of ferric chloride (20 mmol/L) (55-57). All solutions were prepared freshly. Tissue was homogenized in an ice-cooled Tris-HCl buffer (250 mM Tris-HCl, 200 mM sucrose and 5 mM DTT, pH=7.4). Then, 50 μl of tissue homogenate and 150 μl of deionized water was added to 1.5 ml of the FRAP reagent (44). Afterward, the reaction mixture was incubated at 37 °C for 5 min. Finally, the absorbance of developed color was

measured at $\lambda=595$ nm by an Ultrospec 2000®UV spectrophotometer (Pharmacia Biotech, Uppsala, Sweden) (24, 58).

2.9. Statistical analysis

Data are given as Mean \pm SD. Comparison of data sets was performed by the one-way analysis of variance (ANOVA) with Tukey's multiple comparisons as a post hoc test. Values of $P<0.05$ were considered statistically significant.

3. Results

Acute liver failure was evident in thioacetamide-treated animals as judged by the severe increase in serum biomarkers of liver injury (Figure 1). On the other hand, it was found that taurine supplementation (250, 500, and 1000 mg/kg, i.p) decreased serum ALT, AST, LDH, and bilirubin level in thioacetamide-treated rats (Fig-

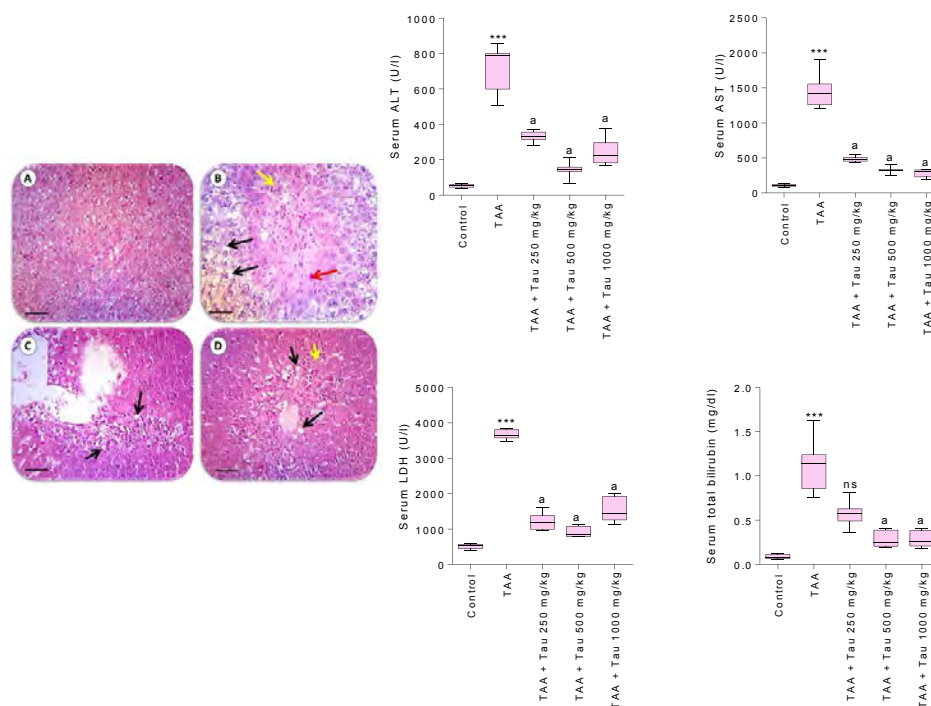


Figure 1. Serum biochemical measurements and liver tissue histopathology. TAA: Thioacetamide; Tau: Taurine. Data are given as Mean \pm SD (n=8).

***Indicates significantly different as compared with the control group ($P<0.001$).

^aIndicates significantly different as compared with TAA group ($P<0.001$).

ns: Not significant as compared with TAA group ($P>0.05$).

Photomicrographs for liver tissue histopathology are adapted from the reference 44. **A:** Control. **B:** Thioacetamide treated rats. **C:** Thioacetamide + Taurine 500 mg/kg. **D:** Thioacetamide + Taurine 1000 mg/kg. Signs of hepatocytes apoptosis (red arrow), fatty changes and ballooning degeneration (black arrow), inflammation (yellow arrow), was developed in thioacetamide-administered animals (**B**). Taurine administration significantly alleviated thioacetamide-induced lesions (**C & D**) and no tissue necrosis was observed in taurine-treated (1000 mg/kg, i.p) animals (**D**).

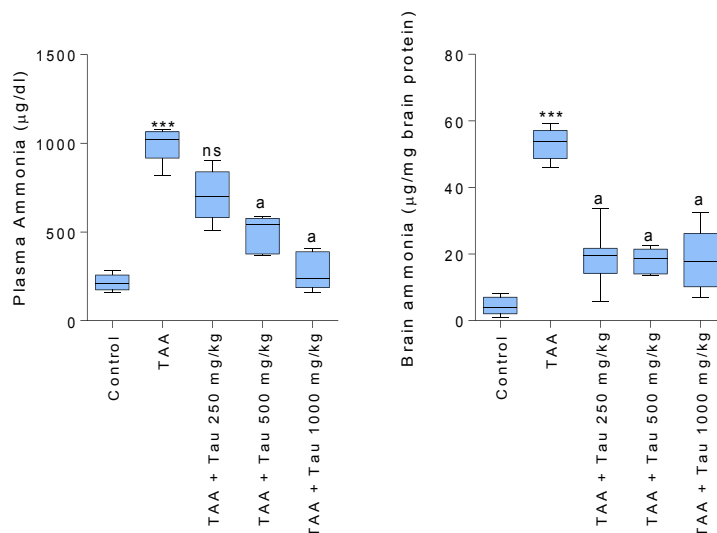


Figure 2. Plasma and brain tissue ammonia level.

Data are given as Mean±SD (n=8).

***Indicates significantly different as compared with the control group ($P<0.001$).

^aIndicates significantly different as compared with TAA group ($P<0.001$).

ns: Not significant as compared with TAA group ($P>0.05$).

ure 1). Liver tissue histopathological changes including tissue necrosis, ballooning degeneration, fatty changes, and inflammation were evident in

thioacetamide group, which indicates severe liver injury and hepatic failure (Figure 1). It was found that taurine treatment (250, 500, and 1000 mg/

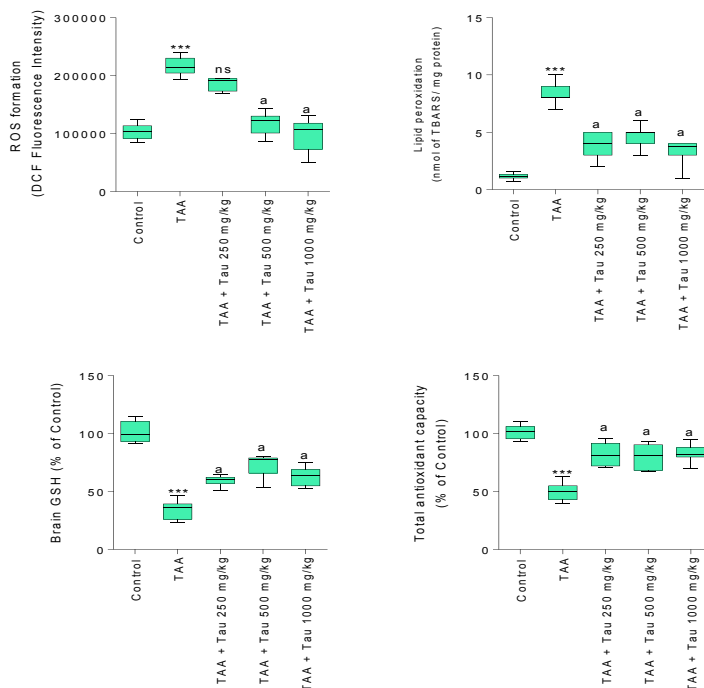


Figure 3. Effect of taurine supplementation on brain tissue markers of oxidative stress in hyperammonemic animals.

Data are given as Mean±SD (n=8).

***Indicates significantly different as compared with the control group ($P<0.001$).

^aIndicates significantly different as compared with TAA group ($P<0.001$).

ns: Not significant as compared with TAA group ($P>0.05$).

kg, i.p) mitigated liver lesions in comparison with thioacetamide-treated animals (Figure 1).

Assessment of brain and plasma ammonia level revealed a significant increase of this chemical in both plasma and brain tissue of thioacetamide-treated rats in comparison with control group (Figure 2). On the other hand, it was found that plasma, as well as brain tissue ammonia level, was lower in taurine-supplemented (250, 500, and 1000 mg/kg, i.p) animals (Figure 2).

Brain tissue markers of oxidative stress were elevated in the thioacetamide model of acute liver failure (Figure 3). A significant increase in tissue ROS level along with elevated lipid peroxidation was detected in the brain tissue of thioacetamide-treated group (Figure 3). Furthermore, brain glutathione level was lower and tissue antioxidant capacity was decreased in thioacetamide-treated animals (Figure 3). It was found that taurine (250, 500, and 1000 mg/kg, i.p) alleviated brain tissue markers of oxidative stress when administered to thioacetamide-treated rats (Figure 3).

It's noteworthy that the sole taurine (1000 mg/kg, i.p) didn't change the markers assessed in the current investigation as compared with the control group.

4. Discussion

The brain is an important target organ for ammonia toxicity during HE with different etiologies (4, 59). The occurrence of oxidative stress in the brain tissue is an important feature of hyperammonemia and HE (4, 59). Hence, antioxidants and protective agents might be of value against this complication. Taurine is an amino acid abundantly found in human tissues, especially in the brain. Taurine is an antioxidant, osmoregulator, membrane stabilizer, and, probably, a neurotransmitter (16-18). On the other hand, risk assessment investigations revealed that this amino acid is "very safe" even at high doses (60). In the current investigation, it was found that taurine supplementation (150, 500, and 1000 mg/kg, i.p) to animals with hepatic failure and hyperammonemia alleviated oxidative stress and its associated complications in the brain tissue.

It has been repeatedly shown that severe oxidative stress occurs in the brain tissue exposed

to the pathological concentrations of ammonia (10, 11, 13). Decreased tissue antioxidant capacity, severe lipid peroxidation, and glutathione reservoirs depletion of the brain tissue are reported in the experimental models of HE (10, 11, 13, 61). In accordance with previous studies, we found that brain ROS level was significantly elevated in thioacetamide-treated animals. On the other hand, decreased tissue antioxidant capacity, glutathione depletion, and lipid peroxidation was detected in the rat model of fulminant hepatic failure (Figure 3). It was found that taurine supplementation (250, 500, and 1000 mg/kg, i.p) effectively attenuated markers of oxidative stress in the brain tissue of hyperammonemic animals (Figure 3). Hence, a major part of the protective properties of taurine against ammonia-induced neurotoxicity might be mediated through its antioxidant capacity.

Previous investigations mentioned that taurine and its related structures could attenuate lipid peroxidation, preserve the intracellular stores of GSH, and prevent the loss of antioxidant enzymes activities (21, 62-70). It has also been found that taurine boosts the activity of glutathione-dependent cellular defense mechanisms such as glutathione-s-transferase (GST), glutathione peroxidase (GPx), and glutathione reductase (GR) enzymes (21, 62-70). Although some investigations questioned the direct effect of taurine on reactive species (71), this amino acid might be able to scavenge oxygen radicals (72). On the other hand, as an indirect antioxidant, taurine has been proposed as a membrane stabilizer, which could manage membrane organizations, prevent cellular ion leakage and water influx, and finally avoid cell swelling (73, 74).

The neuroprotective properties of taurine are extensively reviewed (31-33, 39). It has been found that several neurological complications, as well as xenobiotics-induced neurotoxicity, might benefit from exogenous taurine supplementation (38-41). As mentioned, ammonia is a neurotoxin with deleterious effects on CNS (75-77). It has been found that increased brain ammonia level leads to oxidative stress, alterations in pH and Ca²⁺ homeostasis, bioenergetic failure, and electrophysiological disturbances in CNS (75-77). This implies that taurine supplementation

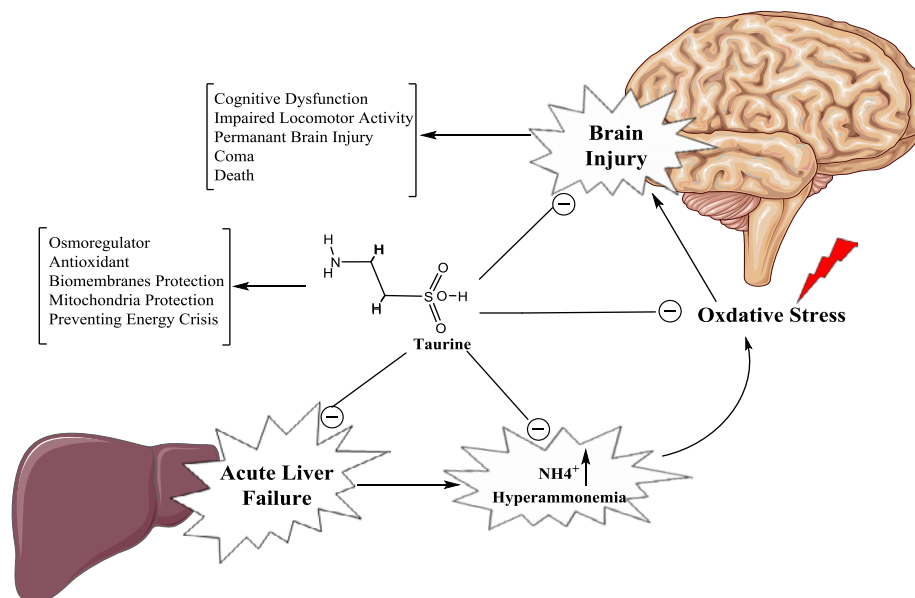


Figure 4. Schematic representation of the effect of taurine on hyperammonemia and hepatic encephalopathy-induced brain injury.

might be a valuable therapeutic option against ammonia-induced oxidative stress and neurotoxicity (Figure 4).

Although the precise mechanism of ammonia-induced free radical production and oxidative stress is not clear, a major source of oxidative stress might be attributed to the adverse effect of ammonia on brain mitochondria (78-82). It has been found that ammonia caused a significant increase in brain mitochondrial ROS (83, 84). Previously, we found that taurine significantly mitigated ammonia-induced mitochondrial dysfunction (83, 84). Hence, mitochondrial protecting properties of taurine might be involved, at least in part, in the antioxidant properties of this chemical in brain tissue of hyperammonemic models.

Previously, we found that taurine administration effectively lowered blood and brain ammonia and its associated complications such as locomotor activity disturbances in different models of acute and chronic liver injury (Figure 4) (44). In the current study, the significant role of taurine in attenuating ammonia-induced oxidative stress in the brain tissue was demonstrated (Figure 4).

These findings might indicate the importance of taurine in preventing ammonia-induced neurotoxicity. Hence, taurine supplementation might be considered as a therapeutic approach to ameliorate brain damage and neurological disorders during hyperammonemia. HE and hyperammonemia is a multifaceted and complex complication, which affects several organs. Hence, future investigations will reveal the clinical significance of the data presented in the current study and the therapeutic value of taurine against hyperammonemia-induced CNS injury.

Acknowledgment

The authors thank Pharmaceutical Sciences Research Center (PSRC) and the Vice-Chancellor of Research Affairs of Shiraz University of Medical Sciences for providing technical and financial support (Grant number: 95-01-36-12042/94-01-36-9823) of the current investigation.

Conflict of Interest

None declared.

5. References

1. Felipo V. Hepatic encephalopathy: effects of liver failure on brain function. *Nature Rev Neurosci.* 2013;14;851-8.
2. Shawcross D, Jalan R. The pathophysiologic basis of hepatic encephalopathy: central role for ammonia and inflammation. *Cell Mol Life Sci.* 2005;62;2295-304.

3. Albrecht J, Jones EA. Hepatic encephalopathy: molecular mechanisms underlying the clinical syndrome. *J Neurol Sci.* 1999;170;138-46.
4. Dasarathy S, Mookerjee RP, Rackayova V, Thrane VR, Vairappan B, Ott P, Rose CF. Ammonia toxicity: from head to toe? *Metab Brain Dis.* 2017;32;529-38.
5. Norenberg M. Oxidative and nitrosative stress in ammonia neurotoxicity. *Hepatology.* 2003;37;245-248.
6. Bosoi CR, Rose CF. Identifying the direct effects of ammonia on the brain. *Metab Brain Dis.* 2008;24;95-102.
7. Wang Q, Wang Y, Yu Z, Li D, Jia B, Li J, Guan K, Zhou Y, Chen Y, Kan Q. Ammonia-induced energy disorders interfere with bilirubin metabolism in hepatocytes. *Arch Biochem Biophys.* 2014;555-556;16-22.
8. Felipo V, Butterworth RF. Mitochondrial dysfunction in acute hyperammonemia. *Neurochem Int.* 2002;40;487-491.
9. Murthy Crk, Rama Rao Kv, Bai G, Norenberg MD. Ammonia-induced production of free radicals in primary cultures of rat astrocytes. *J Neurosci Res.* 2001;66;282-8.
10. Bemeur C, Desjardins P, Butterworth RF. Evidence for oxidative/nitrosative stress in the pathogenesis of hepatic encephalopathy. *Metab Brain Dis.* 2010;25;3-9.
11. Skowrońska M, Albrecht J. Oxidative and nitrosative stress in ammonia neurotoxicity. *Neurochem Int.* 2013;62;731-7.
12. Görg B, Qvarthkhava N, Bidmon H-J, Palomero-Gallagher N, Kircheis G, Zilles K, Häussinger D. Oxidative stress markers in the brain of patients with cirrhosis and hepatic encephalopathy. *Hepatology.* 2010;52;256-65.
13. Häussinger D, Schliess F. Pathogenetic mechanisms of hepatic encephalopathy. *Gut.* 2008;57;1156-65.
14. Bouckenoghe T, Remacle C, Reusens B. Is taurine a functional nutrient? *Curr Opin Clin Nut Metab Care.* 2006;9;728-33.
15. Huxtable RJ, others. Physiological actions of taurine. *Physiol Rev.* 1992;72;101-63.
16. Hansen SH, Andersen ML, Birkedal H, Cornett C, Wibrand F, The Important Role of Taurine in Oxidative Metabolism, in Taurine 6, S.S. Oja and P. Saransaari, Editors. 2006, Springer US. p. 129-135.
17. Oja SS, Saransaari P. Taurine as osmoregulator and neuromodulator in the brain. *Metab Brain Dis.* 1996;11;153-64.
18. Schaffer S, Azuma J, Takahashi K, Mozafari M, Why is taurine cytoprotective?, in Taurine 5, 2003, Springer. p. 307-321.
19. Lourenco R, Camilo ME, others. Taurine: a conditionally essential amino acid in humans? An overview in health and disease. *Nutr Hosp.* 2002;17;262-70.
20. Heidari R, Babaei H, Eghbal MA. Cytoprotective Effects of Taurine Against Toxicity Induced by Isoniazid and Hydrazine in Isolated Rat Hepatocytes. *Arch Indust Hyg Toxicol.* 2013;64;201-10.
21. Sinha M, Manna P, Sil PC. Taurine, a conditionally essential amino acid, ameliorates arsenic-induced cytotoxicity in murine hepatocytes. *Toxicol In Vitro.* 2007;21;1419-28.
22. Ghosh M, Pal S, Sil PC. Taurine attenuates nano-copper-induced oxidative hepatic damage via mitochondria-dependent and NF- κ B/TNF- α -mediated pathway. *Toxicol Res.* 2014;3;474-86.
23. Schuller-Levis GB, Park E. Taurine: new implications for an old amino acid. *Microbiol Letter.* 2003;226;195-202.
24. Heidari R, Jamshidzadeh A, Niknahad H, Safari F, Azizi H, Abdoli N, Ommati MM, Khodaei F, Saeedi A, Najibi A. The Hepatoprotection Provided by Taurine and Glycine against Antineoplastic Drugs Induced Liver Injury in an Ex Vivo Model of Normothermic Recirculating Isolated Perfused Rat Liver. *Trend Pharm Sci.* 2016;2;59-76.
25. Heidari R, Babaei H, Eghbal MA. Amodiaquine-induced toxicity in isolated rat hepatocytes and the cytoprotective effects of taurine and/or N-acetyl cysteine. *Res Pharm Sci.* 2014;9;97-105.
26. Karamikhah R, Jamshidzadeh A, Azarpira N, Saeedi A, Heidari R. Propylthiouracil-Induced Liver Injury in Mice and the Protective Role of Taurine. *Pharm Sci.* 2015;21;94-101.
27. Heidari R, Jamshidzadeh A, Keshavarz N, Azarpira N. Mitigation of Methimazole-Induced Hepatic Injury by Taurine in Mice. *Sci Pharm.* 2015;83;143-58.
28. Heidari R, Sadeghi N, Azarpira N, Niknahad H. Sulfasalazine-Induced Hepatic Injury in an Ex Vivo Model of Isolated Perfused Rat Liver and the Protective Role of Taurine. *Pharm Sci.*

2015;21;211-219.

29. Menzie J, Pan C, Prentice H, Wu J-Y. Taurine and central nervous system disorders. *Amino acids*. 2014;46;31-46.

30. Huxtable RJ. Taurine in the central nervous system and the mammalian actions of taurine. *Prog Neurobiol*. 1989;32;471-533.

31. Kumari N, Prentice H, Wu J-Y, Taurine and its neuroprotective role, in Taurine 82013, Springer. p. 19-27.

32. Huxtable RJ, Taurine in nutrition and neurology. Vol. 139. 2013: Springer Science & Business Media.

33. Huxtable RJ. Taurine in the central nervous system and the mammalian actions of taurine. *Prog Neurobiol*. 1989;32;471-533.

34. Foos TM, Wu J-Y. The role of taurine in the central nervous system and the modulation of intracellular calcium homeostasis. *Neurochem Res*. 2002;27;21-26.

35. Wu J-Y, Prentice H. Role of taurine in the central nervous system. *J Biomed Sci*. 2010;17;S1.

36. Saransaari P, Oja SS. Taurine and neural cell damage. *Amino Acids*. 2000;19;509-26.

37. Zhou J, Li Y, Yan G, Bu Q, Lv L, Yang Y, Zhao J, Shao X, Deng Y, Zhu R, others. Protective role of taurine against morphine-induced neurotoxicity in C6 cells via inhibition of oxidative stress. *Neurotox Res*. 2011;20;334-42.

38. Louzada PR, Lima ACP, Mendonça-Silva DL, Noël F, De Mello FG, Ferreira ST. Taurine prevents the neurotoxicity of β -amyloid and glutamate receptor agonists: activation of GABA receptors and possible implications for Alzheimer's disease and other neurological disorders. *The FASEB J*. 2004;18;511-8.

39. El Idrissi A. Taurine improves learning and retention in aged mice. *Neurosci Lett*. 2008;436;19-22.

40. Gao X, Yang X, Zhang B. Neuroprotection of taurine against bilirubin-induced elevation of apoptosis and intracellular free calcium ion in vivo. *Toxicol Mech Methods*. 2011;21;383-7.

41. Leon R, Wu H, Jin Y, Wei J, Buddhala C, Prentice H, Wu J-Y. Protective function of taurine in glutamate-induced apoptosis in cultured neurons. *J Neurosci Res*. 2009;87;1185-94.

42. Tuñón MJ, Alvarez M, Culebras JM, González-Gallego J. An overview of animal models for investigating the pathogenesis and thera-

peutic strategies in acute hepatic failure. *World J Gastroenterol*. 2009;15;3086-98.

43. Bruck R, Aeed H, Shirin H, Matas Z, Zaidel L, Avni Y, Halpern Z. The hydroxyl radical scavengers dimethylsulfoxide and dimethylthiourea protect rats against thioacetamide-induced fulminant hepatic failure. *J Hepatology*. 1999;31;27-38.

44. Heidari R, Jafari F, Khodaei F, Shirazi Yeganeh B, Niknahad H. The Mechanism of Valproic Acid-Induced Fanconi Syndrome Involves Mitochondrial Dysfunction and Oxidative Stress in Rat Kidney. *Nephrology (Carlton, Vic)*. 2017;In-Press.

45. Chatauret N, Desjardins P, Zwingmann C, Rose C, Rao KVR, Butterworth RF. Direct molecular and spectroscopic evidence for increased ammonia removal capacity of skeletal muscle in acute liver failure. *J Hepatol*. 2006;44;1083-8.

46. Moezi L, Heidari R, Amirghofran Z, Nekooeian AA, Monabati A, Dehpour AR. Enhanced anti-ulcer effect of pioglitazone on gastric ulcers in cirrhotic rats: The role of nitric oxide and IL-1b. *Pharmacol Report*. 2013;65;134-43.

47. Heidari R, Babaei H, Roshangar L, Eghbal MA. Effects of Enzyme Induction and/or Glutathione Depletion on Methimazole-Induced Hepatotoxicity in Mice and the Protective Role of N-Acetylcysteine. *Adv Pharm Bull*. 2014;4;21-8.

48. Gupta R, Dubey DK, Kannan GM, Flora SJS. Concomitant administration of Moringa oleifera seed powder in the remediation of arsenic-induced oxidative stress in mouse. *Cell Biol Int*. 2007;31;44-56.

49. Heidari R, Moezi L, Asadi B, Ommati MM, Azarpira N. Hepatoprotective effect of boldine in a bile duct ligated rat model of cholestasis/cirrhosis. *PharmaNutrition*. 2017;5;109-17.

50. Succi DJ, Bjugstad KB, Jones HC, Pattisapu JV, Arendash GW. Evidence that oxidative stress is associated with the pathophysiology of inherited hydrocephalus in the H-Tx rat model. *Exp Neurol*. 1999;155;109-17.

51. Niknahad H, Hosseini H, Gozashtegan F, Ebrahimi F, Azarpira N, Abdoli N, Heidari R. The Hepatoprotective Role of Thiol Reductants against Mitoxantrone-Induced Liver Injury. *Trend Pharm Sci*. 2017;3;113-7.

52. Heidari R, Babaei H, Roshangar L, Eghbal MA. Effects of Enzyme Induction and/or Glutathione Depletion on Methimazole-Induced Hepatotoxicity in Mice and the Protective Role of

- N-Acetylcysteine. *Adv Pharm Bull.* 2014;4:21-8.
53. Jamshidzadeh A, Heidari R, Latifpour Z, Ommati MM, Abdoli N, Mousavi S, et al. Carnosine ameliorates liver fibrosis and hyperammonemia in cirrhotic rats. *Clin Res Hepatol Gastroenterol.* 2017;41:424-34.
54. Katalinic V, Modun D, Music I, Boban M. Gender differences in antioxidant capacity of rat tissues determined by 2,2'-azinobis (3-ethylbenzothiazoline 6-sulfonate; ABTS) and ferric reducing antioxidant power (FRAP) assays. *Comp Biochem Physiol C Toxicol Pharmacol.* 2005;140:47-52.
55. Najafi N, Jamshidzadeh A, Fallahzadeh H, Omidi M, Abdoli N, Najibi A, Azarpira N, Heidari R, Niknahad H. Valproic Acid-Induced Hepatotoxicity and the Protective Role of Thiol Reductants. *Trend Pharm Sci.* 2017;3:63-70.
56. Heidari R, Taheri V, Rahimi HR, Shirazi Yeganeh B, Niknahad H, Najibi A. Sulfasalazine-induced renal injury in rats and the protective role of thiol-reductants. *Renal Failure.* 2016;38:137-41.
57. Hossein N, Akram J, Reza H, Narges A, Mohammad Mehdi O, Faezeh J, Mahdi Z, Behnam A. The Postulated Hepatotoxic Metabolite of Methimazole Causes Mitochondrial Dysfunction and Energy Metabolism Disturbances in Liver. *Pharm Sci.* 2016;22:217-26.
58. Alía M, Horcajo C, Bravo L, Goya L. Effect of grape antioxidant dietary fiber on the total antioxidant capacity and the activity of liver antioxidant enzymes in rats. *Nut Res.* 2003;23:1251-67.
59. Braissant O, McLin VA, Cudalbu C. Ammonia toxicity to the brain. *J Inherit Metab Dis.* 2013;36:595-612.
60. Shao A, Hathcock JN. Risk assessment for the amino acids taurine, l-glutamine and l-arginine. *Regul Toxicol Pharmacol.* 2008;50:376-99.
61. Túnez I, Muñoz MC, Medina FJ, Salcedo M, Feijóo M, Montilla P. Comparison of melatonin, vitamin E and L-carnitine in the treatment of neuro- and hepatotoxicity induced by thioacetamide. *Cell Biochem Func.* 2007;25:119-27.
62. Sevgiler Y, Karaytug S, Karayakar F. Antioxidative effects of N-acetylcysteine, lipoic acid, taurine, and curcumin in the muscle of *Cyprinus carpio* L. exposed to cadmium. *Arh Hig Rada Toksikol.* 2011;62:1-9.
63. Tabassum H, Rehman H, Banerjee BD, Raisuddin S, Parvez S. Attenuation of tamoxifen-induced hepatotoxicity by taurine in mice. *Clin Chim Act.* 2006;370:129-36.
64. Acharya M, Lau-Cam CA, Comparative Evaluation of the Effects of Taurine and Thiotaurine on Alterations of the Cellular Redox Status and Activities of Antioxidant and Glutathione-Related Enzymes by Acetaminophen in the Rat, in Taurine 8, A.E. Idrissi and W.J. L'Amoreaux, Editors. 2013, Springer New York. p. 199-215.
65. Ozden S, Catalgol B, Gezginci-Oktayoglu S, Arda-Pirincci P, Bolkent S, Alpertunga B. Methiocarb-induced oxidative damage following subacute exposure and the protective effects of vitamin E and taurine in rats. *Food Chem Toxicol.* 2009;47:1676-84.
66. Shalby AB, Assaf N, Ahmed HH. Possible mechanisms for N-acetyl cysteine and taurine in ameliorating acute renal failure induced by cisplatin in rats. *Toxicol Mech Methods.* 2011;21:538-46.
67. El-Sayed WM, Al-Kahtani MA, Abdel-Moneim AM. Prophylactic and therapeutic effects of taurine against aluminum-induced acute hepatotoxicity in mice. *J Hazard Mater.* 2011;192:880-6.
68. Manna P, Sinha M, Sil P. Taurine plays a beneficial role against cadmium-induced oxidative renal dysfunction. *Amino Acids.* 2009;36:417-28.
69. Das J, Ghosh J, Manna P, Sil PC. Taurine protects acetaminophen-induced oxidative damage in mice kidney through APAP urinary excretion and CYP2E1 inactivation. *Toxicology.* 2010;269:24-34.
70. Das J, Ghosh J, Manna P, Sinha M, Sil PC. Taurine protects rat testes against NaAsO₂-induced oxidative stress and apoptosis via mitochondrial dependent and independent pathways. *Toxicol Lett.* 2009;187:201-10.
71. Hansen SH, Andersen ML, Cornett C, Gradinaru R, Grunnet N. A role for taurine in mitochondrial function. *J Biomed Sci.* 2010;17:S23.
72. Oliveira MWS, Minotto JB, de Oliveira MR, Zanotto-Filho A, Behr GA, Rocha RF, Moreira JCF, Klamt F. Scavenging and antioxidant potential of physiological taurine concentrations against different reactive oxygen/nitrogen species. *Pharmacol Report.* 2010;62:185-93.
73. Timbrell JA, Seabra V, Waterfield CJ. The in vivo and in vitro protective properties of tau-

- rine. *Gen Pharmacol*. 1995;26;453-62.
74. Ripps H, Shen W. Review: taurine: a "very essential" amino acid. *Mol Vision*. 2012;18;2673.
75. Lemberg A, Fernández MA. Hepatic encephalopathy, ammonia, glutamate, glutamine and oxidative stress. *Ann Hepatol*. 2009;8;95-102.
76. Felipo V, Butterworth RF. Neurobiology of ammonia. *Prog Neurobiol*. 2002;67;259-79.
77. Norenberg MD. Oxidative and nitrosative stress in ammonia neurotoxicity. *Hepatology*. 2003;37;245-8.
78. Rao KVR, Jayakumar AR, Norenberg MD. Ammonia Neurotoxicity: Role of the Mitochondrial Permeability Transition. *J Bioenerg Biomembr*. 2003;18;113-27.
79. Rama Rao KV, Norenberg MD. Brain energy metabolism and mitochondrial dysfunction in acute and chronic hepatic encephalopathy. *Neurochem Int*. 2012;60;697-706.
80. Ott P, Clemmesen O, Larsen FS. Cerebral metabolic disturbances in the brain during acute liver failure: From hyperammonemia to energy failure and proteolysis. *Neurochem Int*. 2005;47;13-8.
81. Alsamri MT, Al-Hammadi S, Shaban S, Alshamsi A, Balhaj G, Pramathan T, Souid A-K. Impaired Forebrain Cellular Bioenergetics Following Acute Exposure to Ammonia. *J Clin Toxicol*. 2013;4:189.
82. Felipo V, Butterworth RF. Neurobiology of ammonia. *Prog Neurobiol*. 2002;67;259-79.
83. Niknahad H, Jamshidzadeh A, Heidari R, Zarei M, Ommati MM. Ammonia-induced mitochondrial dysfunction and energy metabolism disturbances in isolated brain and liver mitochondria, and the effect of taurine administration: relevance to hepatic encephalopathy treatment. *Clin Exp Hepatol*. 2017;3.
84. Jamshidzadeh A, Heidari R, Abasvali M, Zarei M, Ommati MM, Abdoli N, Khodaei F, Yeganeh Y, Jafari F, Zarei A, Latifpour Z, Mardani E, Azarpira N, Asadi B, Najibi A. Taurine treatment preserves brain and liver mitochondrial function in a rat model of fulminant hepatic failure and hyperammonemia. *Biomed Pharmacother*. 2017;86;514-20.

