



## Zoledronic acid-induced mitochondrial impairment, inflammation, and oxidative stress in the rat kidney

Heresh Rezaei<sup>1</sup>; PhD Candidate,  Ayehe Rouhani<sup>1</sup>; Pharm D, Jale Yüzügülen<sup>2</sup>; PhD, Fatemeh Ghaderi<sup>1</sup>; Pharm D, Rahil Fazlinezhad<sup>1</sup>; Pharm D, Mohammad Reza Kiafar<sup>1</sup>; Pharm D, Zahra Honarpishefard<sup>1</sup>; Pharm D, Pargol Matinpour<sup>2</sup>; Pharm D, Abdollah Arjmand<sup>3</sup>; PhD Candidate, Negar Azarpira<sup>4</sup>; PhD, Seyyed Mohammad Amin Kashani<sup>1</sup>; Pharm D, Forouzan Khodaei<sup>1</sup>; PhD, Akram Jamshidzadeh<sup>1</sup>; PhD, Reza Heidari<sup>1\*</sup>; PhD, 

<sup>1</sup>Pharmaceutical Sciences Research Center, Shiraz University of Medical Sciences, Shiraz, Iran

<sup>2</sup>Eastern Mediterranean University, Faculty of Pharmacy, Famagusta, North Cyprus, Turkey

<sup>3</sup>Department of Pharmacology and Toxicology, Shahid Beheshti University of Medical Sciences, Faculty of Pharmacy, Tehran, Iran

<sup>4</sup>Transplant Research Center, Shiraz University of Medical Sciences, Shiraz, Iran

### Abstract

Zoledronic acid (ZLD) is a bisphosphonate drug widely administered against pathological conditions such as hypercalcemia of malignancy, osteoporosis, bone metastases from solid tumors, and multiple myeloma. Unfortunately, renal injury is a serious and dose-limiting adverse effect of ZLD. There is no specific mechanism for ZLD-induced renal damage. The current study aimed to assess the effects of ZLD (10 and 15 mg/kg, i.p., single dose) on the rat kidney. In this regard, several parameters, including oxidative stress biomarkers, serum level of BUN and creatinine, inflammatory cytokines, kidney histopathology, and indices of mitochondrial function were assessed. A significant increase in serum Cr and BUN revealed renal injury. Moreover, kidney histopathological changes, including interstitial inflammation, tissue necrosis, and tubular atrophy, were detected in ZLD-treated rats. Biomarkers of oxidative stress, including a significant increase in reactive oxygen species (ROS), depletion of kidney glutathione (GSH) stores, increased lipid peroxidation, and suppression of the total antioxidant capacity, were detected in ZLD-treated animals. ZLD also significantly increased renal levels of TNF- $\alpha$ , IL-6, and IL-1 $\beta$ . ZLD exposure was also associated with significantly decreased mitochondrial dehydrogenases activity, mitochondrial depolarization, mitochondrial permeabilization, and ATP depletion. These data highlight mitochondrial dysfunction, inflammatory response, and oxidative stress as potential mechanisms in ZLD-induced kidney injury.

**Keywords:** Bisphosphonates; Drug safety; Mitochondrial dysfunction; Kidney Injury; Renal Failure; Pharmacotherapy

Please cite this article as: Rezaei H, Rouhani A, Yüzügülen J, Ghaderi F, Fazlinezhad R, Kiafar MR, et al. Zoledronic acid-induced mitochondrial impairment, inflammation, and oxidative stress in the rat kidney. Trends in Pharmaceutical Sciences. 2023;9(4):243-252. doi: 10.30476/TIPS.2023.100490.1218

### 1. Introduction

Zoledronic acid (ZLD) is a bisphosphonate drug widely administered against various pathologies, including hypercalcemia of malignancy, bone metastases from solid tumors, osteoporosis, and multiple myeloma (1). However, some serious

adverse effects, such as renal injury, are associated with ZLD administration (2-5). ZLD-induced kidney injury could lead to acute renal failure (3, 6). Unfortunately, adverse effects such as renal injury could limit the effectiveness of ZLD or its use in clinical settings. Hence, finding potential mechanisms of organ injury induced by this drug could pave the way for preventing/managing this profound adverse effect.

*Corresponding Author:* Heidari, Reza, Pharmaceutical Sciences Research Center, Shiraz University of Medical Sciences, Shiraz, Iran  
Email: mahlahosseini318@gmail.com

Although there is no well-known mechanism(s) for ZLD-induced kidney injury, some studies mentioned that oxidative stress and its associated complications could be involved in this adverse drug reaction (7, 8). It should be noted that all findings on the effects of oxidative stress in renal cells are obtained from *in vitro* studies (HEK-293 and HTK-2 cell lines) (7, 8). In this regard, we decided to evaluate the effects of ZLD on several biomarkers of oxidative stress *in vivo*. These data could help identify the mechanism of kidney injury induced by this drug and develop therapeutic strategies against this complication.

Mitochondria play a pivotal role in renal tissue (9, 10). Actually, these organelles provide a high level of ATP, which is critical for processes such as the reabsorption of several compounds from the renal tubule (11-13). Hence, several diseases or various xenobiotics could affect mitochondrial function in the kidney tissue (9). Therefore, the mechanism of renal damage induced by xenobiotics (e.g., drugs) could rely on mitochondrial injury and mitochondria-related cell death (10, 14). Moreover, it should be mentioned that mitochondrial damage and oxidative stress are interactive events (9, 14-16). In the current study, the effect of ZLD on renal mitochondria has been investigated to shed light on the mechanism of adverse reactions induced by this drug.

As mentioned, there is no specific mechanism for ZLD-induced renal damage in the *in vivo* experimental models or human cases. Hence, in the current study, we evaluated the effects of oxidative stress, inflammatory response, and mitochondrial impairment in the pathophysiology of ZLD-induced renal damage. These data could help progress preventive/therapeutic options against ZLD-induced kidney injury.

## 2. Materials and methods

### 2.1. Reagents

3-(N-morpholino) propane sulfonic acid, dithiothreitol, bovine serum albumin, malondialdehyde, 3-[4,5dimethylthiazol-2-yl]-2,5-diphenyltetrazolium bromide (MTT), reduced glutathione, methanol HPLC grade, 4,2 Hydroxyethyl,1-piperazineethanesulfonic acid (HEPES), iodoacetic acid, potassium hydroxide, dimethyl sulfoxide, 2',7'-Dichlorofluorescein diacetate, sodium chloride, sucrose, ethylene glycol-bis (2-aminoethyl

ether)-N, N, N', N'-tetraacetic acid, and Rhodamine 123, were obtained from Sigma Chemical Co. Hydroxymethyl aminomethane hydrochloride, zoledronic acid monohydrate, trichloroacetic acid (TCA), thiobarbituric acid, acetonitrile HPLC grade, and glacial acetic acid were purchased from Merck Co.

### 2.2. Animals and treatments

Mature male rats (Sprague-Dawley, 200±20 g, n=18) were obtained from Shiraz University of Medicine, Shiraz, Iran. Rats were housed in a standard environment (22-24 °C; 12:12 h, photoperiod; and 44±1% relative humidity). All processes on experimental animals were conducted in agreement with the ethical guidelines approved by the Shiraz University of Medical Sciences ethics committee. The ARRIVE guidelines for the care and use of experimental animals were also followed in the current investigation (17). Animals were allocated to three groups (n = 6 rats/group) and treated as follows: A) Control (vehicle-treated); B) ZLD (10 mg/mL, s.c, single dose); C) ZLD (15 mg/kg, s.c, single dose). Twenty-four hours after ZLD administration, rats were anesthetized (thiopental, 100 mg/kg, i.p), and serum and kidney samples were collected.

### 2.3. Sample collection

Urine samples (≈400 µL) were collected when animals were handled. Subsequently, samples were centrifuged (17000 g, 10 min, 4 °C), and the supernatant was used for urinalysis. Animals were anesthetized (100 mg/kg of thiopental, i.p). Blood was collected from the abdominal aorta in VACUSERA® tubes for serum preparation. The kidney tissue was excised and washed in ice-cooled normal saline (4 °C) and used for further measurements. Renal weight index was determined as [wet weight of organ (g) / body weight (g)] × 100.

### 2.4. Reactive oxygen species (ROS) formation

Renal tissue ROS level was determined using dichlorofluorescein diacetate (DCF) (18). Briefly, 10 µL of DCF (10 µM final concentration) was added to 900 µL of KCl, and 100 µL of tissue homogenate (10 % w/v in KCl solution) was added. Subsequently, samples were incubated for 10 minutes at 37 °C (protected from light). Finally, sample fluorescence intensity was assessed using a

FLUOstar Omega<sup>®</sup> fluorimeter ( $\lambda_{\text{excitation}}=485$  nm and  $\lambda_{\text{emission}}=525$  nm) (18).

### 2.5. Renal tissue lipid peroxidation

The thiobarbituric acid reactive substances (TBARS) test assessed renal tissue lipid peroxidation in the rat kidney (18). Briefly, 500  $\mu\text{L}$  of the renal tissue homogenate was treated with 1 mL of a reaction mixture composed of thiobarbituric acid (0.4 %, w/v), trichloroacetic acid (50 % w/v), and meta-phosphoric acid (1% w/v solution); pH=2 (18). The mixture was incubated in a water bath (100 °C) for 40 minutes. Then, 0.5 mL of n-butanol was mixed with samples. Next, samples were centrifuged (10000 $\times$ g, 15 min), and the absorbance of the n-butanol was assessed at  $\lambda=532$  nm (EPOCH<sup>®</sup> multifunctional plate reader, US) (18).

### 2.6. Renal glutathione levels

A method based on the colorimetric assessment of the reaction of Ellman's reagent (dithiobis-2-nitrobenzoic acid) with GSH was used to measure renal GSH content (18). Briefly, 500  $\mu\text{L}$  of the renal tissue homogenate was treated with 20  $\mu\text{L}$  of 50 % w/v trichloroacetic acid (4 °C) and incubated on ice (5 min). Then, samples were mixed well and centrifuged (10000 g, 4 °C, 20 min). The supernatant was treated with 200  $\mu\text{L}$  of Tris buffer (40 mM, 4 °C, pH=8.9) and 20  $\mu\text{L}$  DTNB solution (20 mg in 5 mL methanol, protected from light) and mixed well. Finally, the absorbance was measured at  $\lambda=412$  nm (18).

### 2.7. Ferric-reducing antioxidant power (FRAP)

Renal tissue's total antioxidant power was assessed using the FRAP test (18). The working FRAP solution was prepared (freshly) by mixing acetate buffer (300 mM; pH=3.6) with TPTZ (10 mM in 6 N HCl) and ferric chloride (20 mM  $\text{FeCl}_2 \cdot 6\text{H}_2\text{O}$ ). Then, 100  $\mu\text{L}$  of tissue homogenate was added to 1000  $\mu\text{L}$  of the mentioned FRAP reagent and incubated in a shaker incubator (37 °C, 5 min, protected from light). Finally, sample absorbance was assessed at  $\lambda=593$  nm (18).

### 2.8. Renal histopathological alterations

Tissue samples were fixed in a formalin-containing solution (0.4 % w/v  $\text{NaH}_2\text{PO}_4$ , 0.64 % w/v  $\text{Na}_2\text{HPO}_4$ , and 10 % v/v formaldehyde) in

distilled water (pH=7.4). Next, paraffin-embedded samples were cut (4  $\mu\text{m}$ ) and stained with H&E. Renal histopathological alterations were evaluated using a light microscope (Olympus BX53; Japan) by a pathologist.

### 2.9. Kidney mitochondria isolation

Rat renal mitochondria were isolated using a differential centrifugation procedure (18). Briefly, kidneys were washed with 4 °C saline (NaCl 0.9% w/v) and minced in 4 °C isolation buffer (75 mM mannitol, 0.5 mM EGTA, 220 mM sucrose, 2 mM HEPES, and 0.1 % w/v bovine serum albumin) (pH=7.2). Subsequently, minced tissue was homogenized in fresh isolation buffer (1 g tissue: 10 mL buffer) (18). In the first round of the centrifugation (1000 g, 4 °C, 20 min). Subsequently, the supernatant was centrifuged at 10000 g (20 min at 4 °C) to pellet the mitochondria fraction. The second centrifugation phase was repeated thrice using a fresh buffer medium. Finally, isolated mitochondria were suspended in a buffer (1 g tissue: 5 mL buffer) containing 225 mM sucrose, 75 mM mannitol, and 2 mM HEPES (pH=7.4). The isolated kidney mitochondria were used for further analysis.

### 2.10. Mitochondrial dehydrogenases activity

A colorimetric technique using MTT was applied to estimate mitochondrial dehydrogenase activity (18). Briefly, a 0.5 mL of isolated mitochondria preparation was incubated with 40  $\mu\text{L}$  of a 0.4 % w/v MTT solution and incubated at 37 °C for 30 minutes (protected from light) (18). Then, samples were centrifuged (17000 g, 10 min), and the pellet was dissolved in 1 mL of dimethyl sulfoxide. Finally, the absorbance at  $\lambda=570$  nm was measured (18).

### 2.11. Mitochondrial ATP levels

An HPLC protocol was used to assess mitochondrial ATP levels (19). Briefly, 1000  $\mu\text{L}$  of the isolated renal mitochondria were treated with 100  $\mu\text{L}$  of 4 °C perchloric acid, incubated on ice (10 min), and centrifuged (20 min, 17000 g, 4 °C). Subsequently, the supernatant was treated with 100  $\mu\text{L}$  of 4 °C KOH (1 M) and filtered (19). Finally, 25  $\mu\text{L}$  of the prepared sample was filtered (0.45  $\mu\text{m}$  filters) and injected into an HPLC system ( $\mu$ -Bondapak C-18 column, 25 cm as the stationary

phase and a mixture of 100 mM potassium hydrogen phosphate mono-basic, 2.5% v/v acetonitrile, and 1 mM tetrabutylammonium hydroxide, pH=7 as the mobile phase; flow rate was 1 mL/min). The UV detector was set at  $\lambda=254$  nm (18, 19).

### 2.12. Mitochondrial swelling

Alterations in samples' absorbance at  $\lambda=540$  nm is a technique to evaluate isolated mitochondria permeabilization and swelling (18). Briefly, fractions of isolated kidney mitochondria were suspended in the pre-warmed (37 °C) mitochondria permeabilization buffer (10 mM HEPES, 70 mM KCl, 125 mM Sucrose, pH=7.2). The absorbance was recorded at a constant temperature of 30 °C during 30 minutes of incubation (EP-OCH-BioTek® multifunctional plate reader with orbital shaking) (18).  $\text{Ca}^{2+}$  (100  $\mu\text{M}$ ) was used as an inducer of mitochondrial permeability. Finally, the maximal mitochondrial swelling amplitude was calculated as maximal swelling amplitude ( $\Delta\text{OD}$ )= (OD1 at  $\lambda=540$  nm) – (OD2 at  $\lambda=540$  nm) (18).

### 2.13. Mitochondrial depolarization

The cationic dye rhodamine 123 (Rhd 123) uptake by mitochondria was applied to assess mitochondrial depolarization (18). Briefly, 0.5 mL of mitochondrial samples were incubated with 20  $\mu\text{L}$  of Rhd 123 (10  $\mu\text{M}$  concentration) and incubated in the dark (30 min, 37 °C) (18). Subsequently, samples were centrifuged (10000 g, 10 min, 4 °C), and the fluorescence intensity of the supernatant was measured ( $\lambda_{\text{excitation}}=485$  nm and  $\lambda_{\text{emission}}=525$  nm) (18).

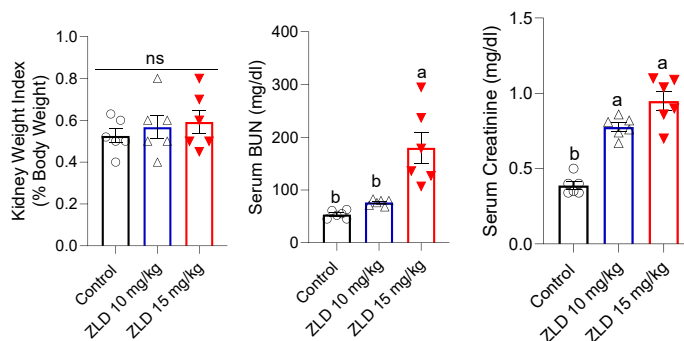
### 2.14. Statistics

Data are represented as mean $\pm$ SD. Data analysis was accomplished by the one-way analysis of variance (ANOVA) and Tukey's multiple comparison test as the post hoc. Renal tissue scores of histopathological alterations are represented as median and quartiles. The Kruskal-Wallis test was used for the analysis of renal histopathological alterations. A  $P<0.05$  was considered a statistically significant difference.

## 3. Results

The current study investigated the nephrotoxic profile of the ZLD as a severe adverse effect of this drug. As shown in Figure 1, ZLD (10 and 15 mg/kg) caused no significant changes in the kidney weight index compared with the control rats (Figure 1). On the other hand, serum BUN was significantly higher in rats that received 15 mg/kg of ZLD (Figure 1). Both doses of ZLD used in the current study caused a substantial increase in serum creatinine levels compared to the control animals (Figure 1). The analysis of the serum of ZLD-exposed animals also revealed significant hypophosphatemia, hypokalemia, and decreased serum  $\text{Na}^+$  at 15 mg/kg of ZLD (Table 1). The lower dose of ZLD (10 mg/kg) caused hypokalemia (Table 1). Urinalysis in ZLD-treated rats revealed a considerable increase in urine glucose, ALP, protein, and  $\gamma$ -GT (Table 1). It was found that the lower dose of ZLD (10 mg/kg) caused a surge in urine levels of  $\gamma$ -GT and ALP (Table 1).

The assessment of the renal tissue biomarkers of oxidative stress revealed significant ROS formation and lipid peroxidation, decreased kidney GSH reservoirs, and depleted tissue anti-



**Figure 1.** Serum biochemical analysis and kidney weight index in ZLD-treated rats. Data sets are represented as mean $\pm$ SD (n=6). Data sets with alphabetical superscripts differ significantly ( $P<0.05$ ). ns: not significant.

**Table 1.** test Urinalysis and some serum biochemical parameters in animals treated with zoledronic acid (ZLD).

	Control	ZLD 10 mg/kg	ZLD 15 mg/kg
<b>Urinalysis</b>			
Protein (mg/dl)	0.4±0.1	0.58±0.16	1.6±0.3 #
ALP (U/l)	1900±344	3455±420 #	3800±456 #
γ-GT (U/l)	2100±231	3879±230 #	4688±465 #
Glucose (mg/dl)	72.0±11	85.0 ±13	124.0±15 #
<b>Serum parameters</b>			
Na <sup>+</sup> (mmol/l)	62.4±5.6	69±6	78±4 #
Phosphate (mg/dl)	2.7±0.15	2.02±0.13	1.62±0.18 #
K <sup>+</sup> (mmol/l)	5.7±1.3	3.24±1 #	3.07±0.49 #

Data are represented as mean ± SD (n=6).

ALP: alkaline phosphatase; γ-GT: γ-glutamyl transferase.

# Indicates significantly different from the control group (P<0.01).

oxidant capacity in ZLD-treated animals (Figure 2). The greater dose of ZLD (15 mg/kg) caused a more severe change in biomarkers of oxidative stress in the current study (Figure 2).

The current study also found that ZLD (10 and 15 mg/kg) could significantly impair mitochondrial function (Figure 3). In this regard, significant decreases in mitochondrial dehydrogenase activity, mitochondrial membrane potential, depletion of mitochondrial ATP reservoirs, and mitochondrial permeabilization were detected in the kidneys of ZLD-treated rats (Figure 3). The effect of the higher dose of ZLD (15 mg/kg) in impairing mitochondrial indices was more significant, except for mitochondrial swelling (Figure 3).

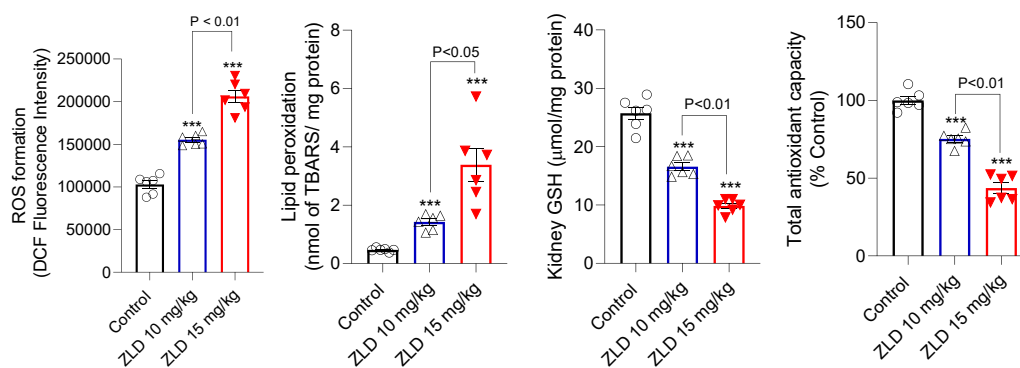
ZLD caused a significant increase in pro-inflammatory levels of cytokines (TNF-α, IL-6, and IL-1β) in the rats' kidneys (Figure 4). The effect of 15 mg/kg of ZLD in increasing pro-inflam-

matory cytokines was more significant in the current study (Figure 4).

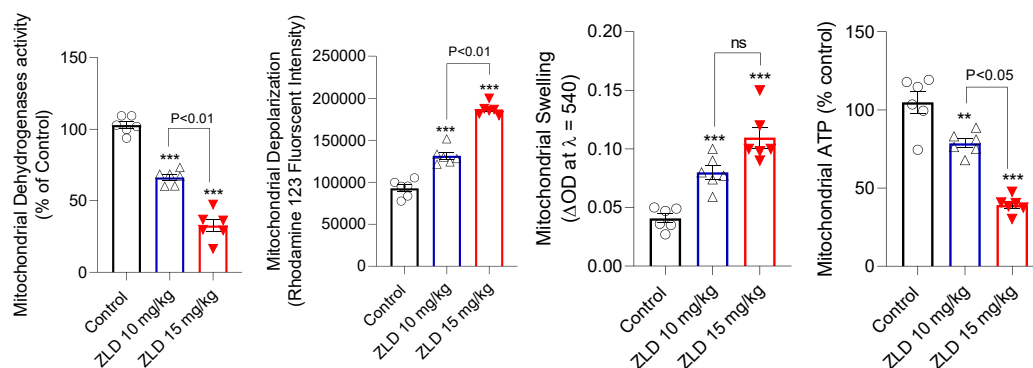
Renal histopathological evaluations in ZLD-treated rats revealed significant tubular atrophy, tissue necrosis, and infiltration of inflammatory cells at both doses of this drug evaluated in the current study (Figure 5).

#### 4. Discussion

Zoledronic acid (ZLD) is clinically administered in various pathological conditions. However, nephrotoxicity is a significant adverse effect coupled with this drug (2-5). Unfortunately, the precise mechanism(s) of kidney injury induced by ZLD is unknown. Moreover, there is no therapeutic agent available to blunt this adverse effect. In the current study, we found that ZLD caused significant oxidative stress in the rat kidney, induced mitochondrial impairment, increased



**Figure 2.** Oxidative stress biomarkers in the renal tissue of ZLD-exposed rats. Data are given as mean±SD (n=6). Asterisks differ significantly from the control group (P<0.001).



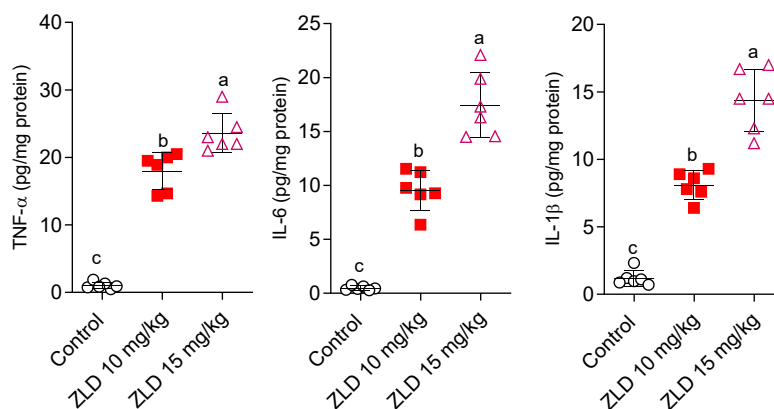
**Figure 3.** Mitochondrial indices in the kidney of zoledronic acid-treated animals. Data are given as mean±SD (n=6). Asterisks differ significantly from the control group (P<0.001).

pro-inflammatory cytokines levels, and caused substantial histopathological alterations in the rat kidney. These findings indicate ZLD as a nephrotoxic agent (e.g., at high dose or short interval use). Therefore, this serious adverse effect should be considered in clinical settings. On the other hand, based on the mentioned mechanisms, therapeutic agents (e.g., antioxidants and mitochondria-protecting agents) could be considered for managing ZLD-induced renal injury.

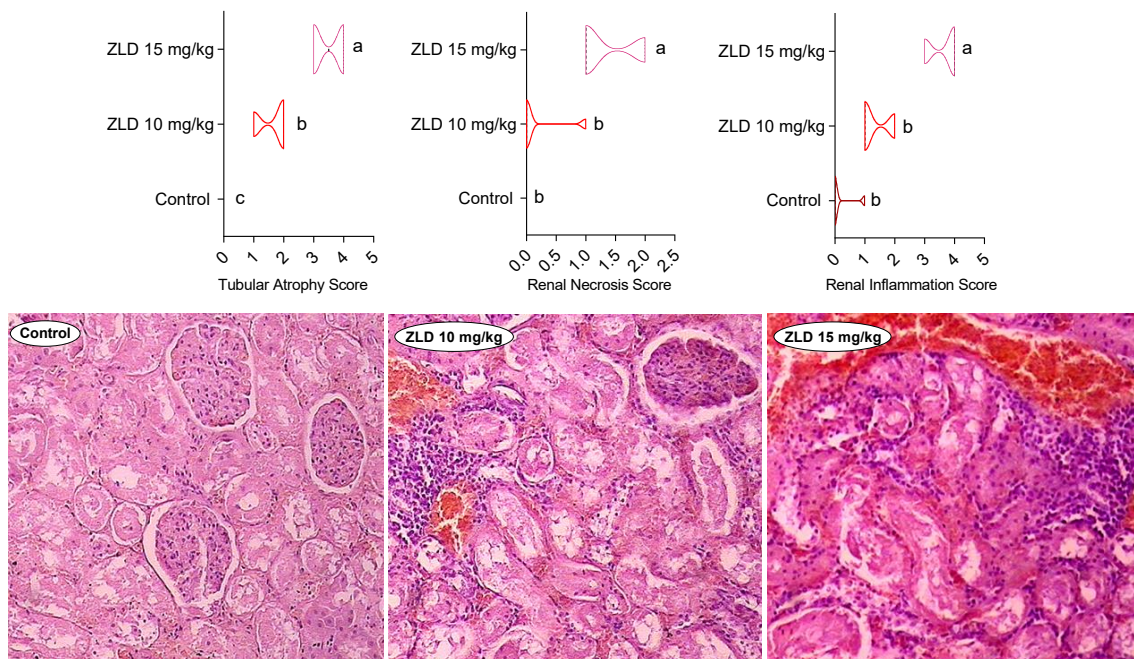
In the current study, we found that oxidative stress and its associated events could play a pivotal role in ZLD-induced renal injury (Figure 2). The effect of ZLD on oxidative stress markers in the *in vitro* experiments (e.g., HTK-2 and HEK-293) is also reported (7, 8). Our data align with these studies, indicating the role of oxidative stress in the cytotoxicity of ZLD *in vitro*. However, the current study might be one of the few investigations that propose the occurrence of oxidative

stress induced by ZLD as a critical mechanism of toxicity caused by this drug *in vivo*. As oxidative stress plays a fundamental role in the pathogenesis of ZLD-induced renal injury, administering safe and clinically applicable agents (e.g., N-acetylcysteine) could find therapeutic significance in this complication (19-23). It should be mentioned here that oxidative stress is a mechanism related to other events, such as mitochondrial impairment and inflammatory response. The role of mitochondrial dysfunction and renal inflammation in the mechanism of ZLD nephrotoxicity are discussed in the following sections.

Mitochondria are crucial intracellular targets for xenobiotics-induced organ injury (23-26). Renal mitochondria seem to be critical targets for ZLD-induced organ injury. In the current study, we found that renal mitochondrial indices, including ATP levels, permeability, membrane potential, and dehydrogenase activity, were significantly



**Figure 4.** Kidney level of pro-inflammatory cytokines in the kidney of zoledronic acid (ZLD)-treated rats. Data are given as mean±SD (n=6). Data sets with different superscripts are significantly different (P<0.05).



**Figure 5.** Renal histopathological alterations in zoledronic acid (ZLD)-treated rats. Kidney histopathological alterations, including tubular atrophy, necrosis, and interstitial inflammation, were detected (upper graphs) in ZLD-treated animals. Data for histopathological scores are represented as median and quartiles for six slides/group. Data sets with different superscripts are significantly different ( $P < 0.05$ ).

impaired by ZLD (Figure 3). The kidney contains numerous mitochondria that are critically involved in providing sufficient ATP, which is critically needed for vital processes such as chemical reabsorption from renal tubules (13, 19). Therefore, impairing renal mitochondrial function with any etiology (e.g., induced by drugs or diseases) could cause the waste of chemicals such as electrolytes, proteins, glucose, and amino acids in urine (4, 13, 19, 27). This situation is usually known as Fanconi syndrome (13, 19). Several drugs, such as valproic acid, lithium, and ifosfamide, could induce Fanconi syndrome in experimental and clinical settings (13, 19). In the current study, we found that some markers, such as glucose and proteins, and enzymes, such as ALP and  $\gamma$ -GT, were significantly higher in the urine of ZLD-treated rats (Table 1). Moreover, ZLD-treated rats showed hypokalemia and hypophosphatemia (Table 1). These events could be associated with impaired renal mitochondrial function and lack of energy (ATP) for the reabsorption of these chemicals from the renal tubules to the circulation. Interestingly, abnormal mitochondrial shapes were detected in the TEM evaluation of renal biopsies taken from ZLD-treated animals (28). Based on these data, ZLD-induced mitochondrial impairment could play a

critical role in its mechanism of nephrotoxicity. In this regard, using mitochondria-protecting agents in ZLD-treated patients with renal injury could serve as a preventive/therapeutic strategy (29, 30). It should also be mentioned that mitochondria are principal sources of intracellular ROS (31). Therefore, ZLD-induced mitochondrial dysfunction in the kidney could hasten ROS formation and oxidative stress in this organ.

Severe histopathological alterations also have been detected in other experimental models investigating ZLD nephrotoxicity (28). In the current study, we also found that ZLD caused significant tubular atrophy, necrosis, and penetration of inflammatory cells into the renal tissue (Figure 5). These events could be associated with severe oxidative stress induced by this drug. On the other hand, we found that the level of pro-inflammatory cytokines (TNF- $\alpha$ , IL-6, and IL-1 $\beta$ ) was significantly increased. These data could suggest using anti-inflammatory agents against ZLD-associated renal injury.

## 5. Conclusion

Collectively, the data presented in the current study revealed nephrotoxicity as a serious adverse effect associated with ZLD. It should be

mentioned that although ZLD was used in short-term and high doses in the current investigation, in many clinical cases, this drug is used chronically (e.g., for years) (4, 32). Moreover, many other factors, such as background renal diseases as well as patients' age (e.g.,  $\approx$ 60 yo), are risk factors involved in the development of ZLD-induced renal injury (3, 32). Interestingly, case reports indicate significant renal damage and serum electrolyte disturbances induced by long-term use of ZLD (4, 32). These findings mention that investigating the mechanisms of renal dysfunction caused by this drug is noteworthy and might pave the way for developing preventive/therapeutic strategies in

future studies in clinical settings.

### Acknowledgments

The authors thank the Pharmaceutical Sciences Research Center of Shiraz University of Medical Sciences for the technical support of this study. This study was financially supported by the Vice Chancellor of Research Affairs, Shiraz University of Medical Sciences, Shiraz, Iran (Grant: 23195/17231/16457 /17231).

### Conflict of Interest

The authors declare no conflict of interest.

### References

1. Coleman R, Burkinshaw R, Winter M, Neville-Webbe H, Lester J, Woodward E, Brown J. Zoledronic acid. *Expert Opin Drug Saf.* 2011 Jan;10(1):133-45. doi: 10.1517/14740338.2011.540387. Epub 2010 Nov 29. PMID: 21114419.
2. de Roij van Zuijdewijn C, van Dorp W, Florquin S, Roelofs J, Verburgh K. Bisphosphonate nephropathy: A case series and review of the literature. *Br J Clin Pharmacol.* 2021 Sep;87(9):3485-3491. doi: 10.1111/bcp.14780. Epub 2021 Mar 4. PMID: 33595131; PMCID: PMC8451932.
3. Yachoui R. Early onset acute tubular necrosis following single infusion of zoledronate. *Clin Cases Miner Bone Metab.* 2016 May-Aug;13(2):154-156. doi: 10.11138/ccmbm/2016.13.2.154. Epub 2016 Oct 5. PMID: 27920815; PMCID: PMC5119716.
4. Katsunuma R, Mitsumoto K, Mizumoto A, Hirai Y, Nakauchi C, Uzu T. Fanconi Syndrome Associated with Long-term Treatment with Zoledronate. *Intern Med.* 2023 Jul 15;62(14):2103-2105. doi: 10.2169/internalmedicine.0647-22. Epub 2022 Nov 30. PMID: 36450467; PMCID: PMC10400390.
5. Fixen CW, Fixen DR. Renal safety of zoledronic acid for osteoporosis in adults 75 years and older. *Osteoporos Int.* 2022 Nov;33(11):2417-2422. doi: 10.1007/s00198-022-06499-4. Epub 2022 Jul 13. PMID: 35829757.
6. Mazj S, Lichtman SM. Renal dysfunction associated with bisphosphonate use: retrospective analysis of 293 patients with respect to age and other clinical characteristics. *J Clin Oncol.* 2004;22;8039. doi: 10.1200/jco.2004.22.90140.8039.
7. Kara M, Boran T, Öztaş E, Jannuzzi AT, Özden S, Özhan G. Zoledronic acid-induced oxidative damage and endoplasmic reticulum stress-mediated apoptosis in human embryonic kidney (HEK-293) cells. *J Biochem Mol Toxicol.* 2022 Aug;36(8):e23083. doi: 10.1002/jbt.23083. Epub 2022 May 19. PMID: 35587103.
8. Lan Z, Chai K, Jiang Y, Liu X. Characterization of urinary biomarkers and their relevant mechanisms of zoledronate-induced nephrotoxicity using rats and HK-2 cells. *Hum Exp Toxicol.* 2019 May;38(5):598-609. doi: 10.1177/0960327119829527. Epub 2019 Feb 11. PMID: 30744404.
9. Lash LH. Diverse Roles of Mitochondria in Renal Injury from Environmental Toxicants and Therapeutic Drugs. *Int J Mol Sci.* 2021 Apr 17;22(8):4172. doi: 10.3390/ijms22084172. PMID: 33920653; PMCID: PMC8073222.
10. Granata S, Dalla Gassa A, Tomei P, Lupo A, Zaza G. Mitochondria: a new therapeutic target in chronic kidney disease. *Nutr Metab (Lond).* 2015 Nov 25;12:49. doi: 10.1186/s12986-015-0044-z. PMID: 26612997; PMCID: PMC4660721.
11. Chakraborti S, Rahaman SM, Alam MN, Mandal A, Ghosh B, Dey K, Chakraborti T. Na<sup>+</sup>/K<sup>+</sup>-ATPase: A Perspective. In: Chakraborti S, Dhalla NS, editors. Regulation of Membrane Na<sup>+</sup>-K<sup>+</sup> ATPase. Advances in Biochemistry in Health and Disease: Springer International Publishing; 2016. p. 3-30.
12. Bhargava P, Schnellmann RG. Mitochondrial energetics in the kidney. *Nat Rev Nephrol.* 2017 Oct;13(10):629-646. doi: 10.1038/nrneph.2017.107. Epub 2017 Aug 14. PMID:



28804120; PMID: PMC5965678.

13. Heidari R. The footprints of mitochondrial impairment and cellular energy crisis in the pathogenesis of xenobiotics-induced nephrotoxicity, serum electrolytes imbalance, and Fanconi's syndrome: A comprehensive review. *Toxicology*. 2019 Jul 1;423:1-31. doi: 10.1016/j.tox.2019.05.002. Epub 2019 May 13. PMID: 31095988.

14. Li Z, Liu Z, Luo M, Li X, Chen H, Gong S, Zhang M, Zhang Y, Liu H, Li X. The pathological role of damaged organelles in renal tubular epithelial cells in the progression of acute kidney injury. *Cell Death Discov*. 2022 May 2;8(1):239. doi: 10.1038/s41420-022-01034-0. PMID: 35501332; PMID: PMC9061711.

15. Gai Z, Gui T, Kullak-Ublick GA, Li Y, Visentin M. The Role of Mitochondria in Drug-Induced Kidney Injury. *Front Physiol*. 2020 Sep 4;11:1079. doi: 10.3389/fphys.2020.01079. PMID: 33013462; PMID: PMC7500167.

16. Zhang X, Agborbesong E, Li X. The Role of Mitochondria in Acute Kidney Injury and Chronic Kidney Disease and Its Therapeutic Potential. *Int J Mol Sci*. 2021 Oct 19;22(20):11253. doi: 10.3390/ijms222011253. PMID: 34681922; PMID: PMC8537003.

17. Sert NPd, Hurst V, Ahluwalia A, Alam S, Avey MT, Baker M, et al. The ARRIVE guidelines 2.0: Updated guidelines for reporting animal research. *PLoS Biol*. 2020;18:e3000410. doi: 10.1371/journal.pbio.3000410.

18. Heidari R, Niknahad H. The role and study of mitochondrial impairment and oxidative stress in cholestasis. In: Vinken M, editor. *Experimental Cholestasis Research. Methods in Molecular Biology*. 1981. New York, NY: Springer; 2019. p. 117-32.

19. Heidari R, Jafari F, Khodaei F, Shirazi Yeganeh B, Niknahad H. Mechanism of valproic acid-induced Fanconi syndrome involves mitochondrial dysfunction and oxidative stress in rat kidney. *Nephrology (Carlton)*. 2018 Apr;23(4):351-361. doi: 10.1111/nep.13012. PMID: 28141910.

20. Heidari R, Taheri V, Rahimi HR, Shirazi Yeganeh B, Niknahad H, Najibi A. Sulfasalazine-induced renal injury in rats and the protective role of thiol-reductants. *Ren Fail*. 2016;38(1):137-41. doi: 10.3109/0886022X.2015.1096731. Epub 2015 Oct 19. PMID: 26479898.

21. Jamshidzadeh A, Heidari R, Golzar T,

Derakhshanfar A. Effect of Eisenia foetida Extract against Cisplatin-Induced Kidney Injury in Rats. *J Diet Suppl*. 2016;13(5):551-9. doi: 10.3109/19390211.2015.1124163. Epub 2016 Feb 11. PMID: 26864051.

22. Mousavi K, Niknahad H, Li H, Jia Z, Manthari RK, Zhao Y, et al. The activation of nuclear factor-E2-related factor 2 (Nrf2)/heme oxygenase-1 (HO-1) signaling blunts cholestasis-induced liver and kidney injury. *Toxicol Res (Camb)*. 2021 Aug 4;10(4):911-927. doi: 10.1093/toxres/tfab073. PMID: 34484683; PMID: PMC8403611.

23. Shafiekhani M, Ommati MM, Azarpira N, Heidari R, Salarian AA. Glycine supplementation mitigates lead-induced renal injury in mice. *J Exp Pharmacol*. 2019 Feb 18;11:15-22. doi: 10.2147/JEP.S190846. PMID: 30858736; PMID: PMC6385776.

24. Heidari R, Ommati MM, Niknahad H. Drug-induced mitochondrial impairment: Mechanisms and testing systems. In: de Oliveira MR, editor. *Mitochondrial Intoxication: Academic Press*; 2023. p. 49-76.

25. Heidari R, Ommati MM, Niknahad H. Mitochondria as biosynthetic centers and targeted therapeutics. In: Pourahmad J, Rezaei M, editors. *Mitochondrial Metabolism: Academic Press*; 2021. p. 19-47.

26. Heidari R, Ommati MM, Niknahad H. Ammonia. In: de Oliveira MR, editor. *Mitochondrial Intoxication: Academic Press*; 2023. p. 249-70.

27. Hall AM, Bass P, Unwin RJ. Drug-induced renal Fanconi syndrome. *QJM*. 2014 Apr;107(4):261-9. doi: 10.1093/qjmed/hct258. Epub 2013 Dec 24. PMID: 24368854.

28. Sert İU, Kilic O, Akand M, Saglik L, Avunduk MC, Erdemli E. The role of vitamin E in the prevention of zoledronic acid-induced nephrotoxicity in rats: a light and electron microscopy study. *Arch Med Sci*. 2018 Mar;14(2):381-387. doi: 10.5114/aoms.2016.60227. Epub 2016 May 30. PMID: 29593813; PMID: PMC5868662.

29. Heidari R, Behnamrad S, Khodami Z, Ommati MM, Azarpira N, Vazin A. The nephroprotective properties of taurine in colistin-treated mice is mediated through the regulation of mitochondrial function and mitigation of oxidative stress. *Biomed Pharmacother*. 2019 Jan;109:103-111. doi: 10.1016/j.biopha.2018.10.093. Epub

2018 Nov 2. PMID: 30396066.

30. Vazin A, Heidari R, Khodami Z. Curcumin Supplementation Alleviates Polymyxin E-Induced Nephrotoxicity. *J Exp Pharmacol.* 2020 Jun 4;12:129-136. doi: 10.2147/JEP.S255861. PMID: 32581601; PMCID: PMC7280086.

31. Brookes PS, Yoon Y, Robotham JL, Anders MW, Sheu SS. Calcium, ATP, and ROS: a mitochondrial love-hate triangle. *Am J Physiol Cell*

*Physiol.* 2004 Oct;287(4):C817-33. doi: 10.1152/ajpcell.00139.2004. PMID: 15355853.

32. Rahbari-Oskoui F, Fielder O, Ghazemzadeh N, Hennigar R. Prolonged recovery time from zoledronic Acid induced acute tubular necrosis: a case report and review of the literature. *Case Rep Nephrol.* 2013;2013:651246. doi: 10.1155/2013/651246. Epub 2013 Jul 29. PMID: 24527249; PMCID: PMC3914195.