

The dipeptide carnosine alleviates acute pancreatitis in an experimental model

Heresh Rezaei^{1,2}, Saeed Heidari¹, Mohammad Mehdi Ommati^{1,3}, Babak Taheri¹, Forouzan Khodaei¹, Mohammad Ali Dehghani¹, Ayehe Rowhanirad¹, Azadeh Veisi-Goshtasb¹, Zahra Honarpishfard¹, Negar Azarpira⁴, Hossein Niknahad^{1,2*}, Reza Heidari^{1*}

¹Pharmaceutical Sciences Research Center, Shiraz University of Medical Sciences, Shiraz, Iran.

²Department of Pharmacology and Toxicology, School of Pharmacy, Shiraz University of Medical Sciences, Shiraz, Iran.

³Henan Key Laboratory of Environmental and Animal Product Safety, College of Animal Science and Technology, Henan University of Science and Technology, Luoyang 471000, Henan, China.

⁴Transplant Research Center, Shiraz University of Medical Sciences, Shiraz, Iran.

Abstract

Acute pancreatitis (AP) is a severe inflammatory disorder with a significant risk of mortality. However, restricted pharmacological treatments are available against this complication. Carnosine is an endogenous dipeptide with various pharmacological effects, including antioxidative and anti-inflammatory properties. The current study was designed to evaluate the impact of carnosine in an experimental model of AP. For this purpose, mice received arginine (two 4 g/kg doses, one-hour intervals, i.p) to induce AP. Then, animals received carnosine (50, 100, and 200 mg/kg, i.p). Serum levels of amylase, lipase, and glucose were significantly increased ($P < 0.001$) in the current AP model. Moreover, alterations in oxidative stress biomarkers in the pancreas, including ROS formation, decreased antioxidant capacity, lipid peroxidation, and glutathione depletion, were detected in the AP group ($P < 0.001$). A significant increase in the pancreatic level of pro-inflammatory cytokines (TNF- α , IL-6, and IL-1 β) was also evident in the l-arginine-treated mice ($P < 0.001$). The major pancreatic tissue histopathological changes in the current AP model were the infiltration of inflammatory cells to the pancreas tissue, fluid accumulation, and acinar cell vacuolization/necrosis ($P < 0.05$). Carnosine significantly reduced serum biomarkers of pancreas injury, alleviated oxidative stress, decreased pro-inflammatory cytokine levels, and improved histopathological changes in the pancreas of mice with AP ($P < 0.001$). These findings suggest that carnosine is a protective agent in pancreatitis, with its antioxidative and anti-inflammatory properties playing a pivotal role in its mechanisms of action. Further research is needed to confirm these protective effects in clinical studies and assess carnosine safety in AP.

Keywords: Inflammation, Oxidative stress, Pancreas, Peptide, Pharmacotherapy

Please cite this article as: Rezaei H, Heidari S, Ommati MM, Taheri B, Khodaei F, Dehghani MA, et al. The dipeptide carnosine alleviates acute pancreatitis in an experimental model. Trends in Pharmaceutical Sciences. 2024;10(4):285-298. doi: 10.30476/tips.2024.102615.1240

Copyright: ©Trends in Pharmaceutical Sciences. This is an open-access article distributed under the terms of the Creative Commons Attribution-NoDerivatives 4.0 International License. This license allows reusers to copy and distribute the material in any medium or format in unadapted form only, and only so long as attribution is given to the creator. The license allows for commercial use.

1. Introduction

Acute pancreatitis (AP) is a severe

inflammatory disease that can lead to a high mortality rate of up to 50% (1-3). Symptoms of acute pancreatitis can vary from mild abdominal discomfort to a life-threatening condition caused by the release of pancreatic

Corresponding Author: Hossein Niknahad & Reza Heidari, Department of Pharmacology and Toxicology, School of Pharmacy, Shiraz University of Medical Sciences, Shiraz, Iran.
Email address: nikhahadh@sums.ac.ir & rheidari@sums.ac.ir

enzymes into the abdominal cavity (1, 2). Various factors such as gallstones, alcoholism, infections, certain medications, hypertriglyceridemia, and trauma have been implicated in the development of AP (1, 2, 4). AP could lead to serious complications such as systematic inflammatory conditions and multi-organ failure (5-7).

During acute pancreatitis (AP), several critical processes occur in pancreatic tissue. One of the most serious events is the activation of enzymes like amylase and lipase, which results in the autodigestion of the pancreas tissue (8). This autodigestion, induced by pancreatic enzymes, leads to severe accumulation of the inflammatory cells in the pancreas and organ damage (8). This severe inflammatory response could even extend to the surrounding tissues and organs (8). Moreover, AP can give rise to various other changes, including alterations in pancreas vasculature, the formation of fluid-filled sacs or abscesses, tissue necrosis, and organ failure (9, 10).

The management of AP primarily involves eliminating risk factors such as gallstone surgery, cessation of ethanol consumption, eradication of infectious diseases, and administering drugs such as anti-hyperlipidemic agents (10). Various other interventions have also been developed to address AP and its related complications. These interventions include intravenous fluid hydration, prevention of gut microbiota translocation and their products to the systemic circulation (e.g., by administration of probiotic bacteria such as *Lactobacillus* and *Bifidobacterium* strains, that may help maintain a balanced gut microbiota and enhancing gut barrier function), treatment of metabolic complications like hyperglycemia and hypocalcemia, and management of acute pancreatitis-associated sepsis through the use of antibiotics (10). Surgical interventions may also be necessary to remove pancreas tissue, such as parts of necrotized/damaged tissue. Pharmacotherapy for acute pancreatitis includes medications to alleviate pain, such as acetaminophen, tramadol, and meperidine, as well as to treat infections with drugs like ceftriaxone, ampicillin, and imipenem. However, there are currently no drugs available that directly target pancreas tissue or specifically

treat acute pancreatitis.

A variety of experimental models for pancreatitis have been devised to study the disease's pathophysiology and potential treatments (11). Nonetheless, it has been discovered that certain models resolve rapidly and do not result in any fatalities (11). Models like choline-deficient-methionine-supplemented diet-induced pancreatitis also present challenges, including a high mortality rate and inconsistent outcomes (11).

Utilizing L-arginine to induce acute pancreatitis in mice is a recognized technique for studying the pathophysiology of the disease and exploring therapeutic interventions (11, 12). Studies have confirmed that L-arginine can trigger a predictable model of acute pancreatitis in C57BL6 mice (12). The involvement of oxidative stress in pancreas tissue injury is significant in the arginine-induced animal model (12-15). Additionally, there is a noticeable increase in inflammatory cells and immune response in the pancreas of mice with arginine-induced pancreatitis (13-15). These findings suggest that antioxidant compounds and anti-inflammatory agents have the potential to mitigate acute pancreatitis and its associated issues.

Carnosine is a naturally occurring dipeptide molecule composed of β -alanine and L-histidine. This peptide is found in high concentrations in skeletal muscle tissue, the brain, and other tissues throughout the body (16). Carnosine has garnered significant attention due to its biological functions and potential health benefits (16-18). Antioxidant properties, anti-glycation action, and anti-inflammatory activity of carnosine have been repeatedly highlighted in various experimental models (19-22). Interestingly, the protective effects of carnosine on the pancreas tissue, especially the beta cells of the pancreas, have been investigated (in diabetes experimental models) (23, 24). In these studies, it has been found that carnosine could significantly decrease oxidative stress and its complications in the pancreas tissue of diabetic models (23, 24). However, there is no data on the effect of carnosine on acute inflammation, tissue injury, and severe oxidative stress in acute pancreatitis that makes the current study novel.

As mentioned, oxidative stress and inflammation are basic mechanisms involved in the pathogenesis of AP (12-15). Meanwhile, carnosine is known for its anti-inflammatory and antioxidant properties in various experimental models (25, 26). Therefore, this study is designed to evaluate the effect of the dipeptide carnosine in an animal model of AP.

2. Materials and Methods

2.1. Chemicals

Carnosine was purchased from Sigma (St. Louis, MO, USA). 4,2 Hydroxyethyl,1-piperazineethanesulfonic acid, dimethyl sulfoxide (DMSO), D-mannitol, Bovine serum albumin (BSA), thiobarbituric acid, coomassie brilliant blue, sodium citrate, hydroxymethyl amino methane hydrochloride (Tris-HCl), and ethylenediaminetetraacetic acid were purchased from Merck (Darmstadt, Germany).

2.2. Animals

Male C57BL6/J mice (24±2 g) were obtained from the Experimental and Comparative Medicine Research Center of Shiraz University of Medical Sciences, Shiraz, Iran. The animals were housed in plastic cages containing wood-chip bedding, kept at an ambient temperature of 23±2 °C and a relative humidity of about 40%. The mice were given free access to tap water and were fed a standard rodent diet (Behparvar®, Tehran, Iran). Animals were handled according to the animal treatment protocol approved by Shiraz University of Medical Sciences ethics committee (Ethic code #IR.SUMS.AEC.1403.080). The ARRIVE guidelines for laboratory animal care and use were also followed (27).

2.3. Treatments

Animals were allotted to four groups (n=12/group). The treatments were as follows: A) Control (saline-treated; 2.5 ml/kg, i.p); B) l-arginine (two doses of 4 g/kg, i.p, 1 hour apart); C) l-arginine + Carnosine (50 mg/kg, i.p); D) l-arginine + Carnosine (100 mg/kg, i.p); and E) l-arginine + Carnosine (200 mg/

kg, i.p). L-arginine caused acute pancreatitis 72 hours after the last dose administration (12). Then, carnosine was administered daily to animals with AP for three consecutive days. Blood and tissue samples were collected on day four after the first dose of carnosine administration. The selection of the l-arginine-induced acute pancreatitis method was made per established protocols that had been previously established (12). The dose of carnosine was selected based on previous studies, including our research team's investigations on the pharmacological properties of this peptide in various experimental models (26, 28). It should also be mentioned that due to the small size of mice pancreas tissue, we had to use a larger number of animals per group to pool pancreatic tissues in some tests. Meanwhile, about n=4 animals/group were used for histopathological evaluations.

2.4. Plasma biochemistry

Blood samples were obtained from the abdominal aorta and placed in sodium citrate tubes. Subsequently, the samples were subjected to centrifugation at 3000 g for 20 minutes at 4 °C to separate the plasma. The plasma was then analyzed for glucose, amylase, and lipase levels using an autoanalyzer device (Mindray BS-200®) and commercial kits (Pars-Azmoon®, Tehran, Iran).

2.5. Tissue histopathology and organ weight index

The pancreas organ weight index was derived using the formula: organ weight index = [wet organ weight (g)/body weight (g)] × 100. Following this calculation, the tissue samples were carefully preserved in a buffered formalin solution to ensure their proper conservation. Subsequently, sections of the pancreas tissues measuring 4 µm in thickness were prepared by embedding them in paraffin. These sections were then stained with hematoxylin and eosin (H&E) for further analysis. The histopathological lesions of the pancreas

tissue in the current study were scored based on previous investigations in this field (29).

2.6. Reactive oxygen species (ROS) formation

The levels of reactive oxygen species (ROS) in pancreas samples were determined by utilizing 2',7'-dichlorofluorescein diacetate (DCF-DA) as a probe (30, 31). In brief, the pancreas tissue was homogenized in 2 mL of ice-cooled 40 mM Tris-HCl buffer (pH=7.4). Subsequently, 100 μ L of the resulting tissue homogenate was combined with 1 mL of 40 mM Tris-HCl buffer and 5 μ L of DCF-DA (with a final concentration of 10 μ M). The samples were then incubated at 37°C for 10 minutes in the dark. Finally, the fluorescence intensity was measured using a FLUOstar Omega® fluorimeter with an excitation wavelength of 485 nm and an emission wavelength of 525 nm (30, 32, 33).

2.7. Pancreas glutathione (GSH) content

Reduced glutathione (GSH) levels in the pancreas tissue homogenates were measured using the DTNB (5,5'-Dithiobis (2-nitrobenzoic acid)) method (30, 34). Briefly, 500 μ L of tissue homogenate (10% w: v in 40 mM Tris-HCl buffer, pH = 7.4) was combined with 100 μ L of TCA (50% w: v), thoroughly mixed, and then centrifuged (10000 g, 15 min, 4 °C). Subsequently, the supernatant was mixed with 1 mL of PBS (pH=8.9) and 800 μ L of DTNB solution (0.1 M in PBS). The samples were well mixed and incubated at room temperature for 5 minutes (protected from light). Finally, the absorbance was assessed at λ =412 nm (30).

2.8. Lipid peroxidation in the pancreas

The levels of TBARS were measured to assess lipid peroxidation in the pancreatic tissue (30). The reaction mixture contained 500 μ L of tissue homogenate (10% w: v in 40 mM Tris-HCl buffer, pH=7.4) and 1 mL of TBARS assay reagent (comprising thiobarbituric acid, phosphoric acid, and trichloroacetic acid at pH=2).

After thorough mixing, the samples were heated at 100 °C for 45 minutes. Once cooled, the mixture was centrifuged at 10000 g for 10 minutes. The absorbance was then read at λ =532 nm using an EPOCH® plate reader from BioTek® Instruments in the USA (30, 35).

2.9. Ferric reducing antioxidant power (FRAP)

The FRAP assay measures the production of a blue-colored ferrous (Fe^{2+})-tripyridyltriazine complex from the colorless oxidized ferric (Fe^{3+}) form (30, 36). To prepare the FRAP reagent, a mixture of acetate buffer (25 mL of 300 mmol/L, pH=3.6), TPTZ (2.5 mL of 10 mM in 40 mM HCl), and ferric chloride (2.5 mL of 20 mM FeCl_3) was created. Tissue homogenate samples (100 μ L) were then combined with 900 μ L of the FRAP reagent. After an incubation period (37 °C, 5 minutes, in the dark), the absorbance at λ =593 nm was assessed using the EPOCH® plate reader (BioTek® Instruments, USA (30)).

2.10. Pro-inflammatory cytokines in the pancreas tissue

The pro-inflammatory cytokine levels in the pancreatic tissue were measured using commercial kits (37), according to the instructions provided by Karmania-Pars-Gene™ (Kerman, Iran).

2.11. Statistical analysis

The normality of the obtained data was analyzed using the Kolmogorov-Smirnov test (the data has a normal distribution). Then, a one-way analysis of variance (ANOVA) with Tukey's multiple post hoc test at $P < 0.05$ was utilized to compare various experimental groups. The pancreatic histopathological changes (non-parametric data) were evaluated using the Kruskal-Wallis test and the Mann-Whitney U test. A significance level of $P < 0.05$ was considered statistically significant.

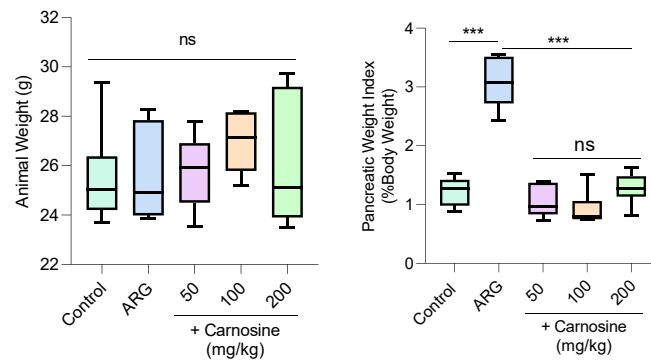


Figure 1. Animal weight and pancreatic weigh index in l-arginine (ARG)-induced acute pancreatitis. Data are represented as boxes and whiskers (min to max). Asterisks indicate a statistically significant difference ($P<0.001$). ns: not significant.

3. Results

Animal weight and pancreas weight index were monitored in the mice model of arginine-induced pancreatitis (Figure 1). Compared with the control group, no significant changes in the animals' weight were observed in the l-arginine-treated mice (Figure 1). However, there was a noticeable increase in the pancreas weight index in the arginine-treated mice compared to the control group (Figure 1). In the current pancreatitis model, it was discovered that carnosine (50, 250, and 500 mg/kg, i.p) significantly reduced the pancreatic weight index (Figure 1).

A significant elevation in serum amylase, lipase, and glucose levels in the current animal model of pancreatitis was demonstrated (Figure 2). The application of carnosine (50, 250, and 500 mg/kg, i.p) led to a signifi-

cant decrease in serum biomarkers of pancreas injury in arginine-treated mice (Figure 2). Notably, the influence of carnosine on serum biochemical measurements exhibited a dose-dependent relationship in this study (Figure 2).

Biomarkers indicating oxidative stress were assessed in the pancreas of mice treated with arginine (Figure 3). Notably, there was a marked rise in ROS levels and lipid peroxidation in the pancreas due to arginine-induced pancreatitis (Figure 3). Additionally, the levels of GSH and total antioxidant capacity in the pancreas of arginine-treated mice were significantly lower compared to the control group (Figure 3). The study revealed that carnosine (50, 250, and 500 mg/kg, i.p) effectively mitigated the oxidative stress biomarkers in the pancreas tissue of arginine-treated mice (Fig-

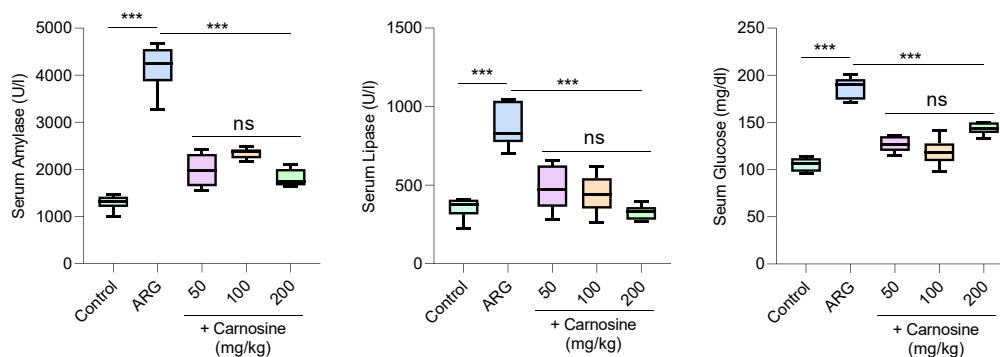


Figure 2. Serum biomarkers of pancreatic injury in l-arginine (ARG) model of acute pancreatitis. Data are represented as box and whiskers (min to max). Asterisks indicate a statistically significant difference ($P<0.001$). ns: not significant.

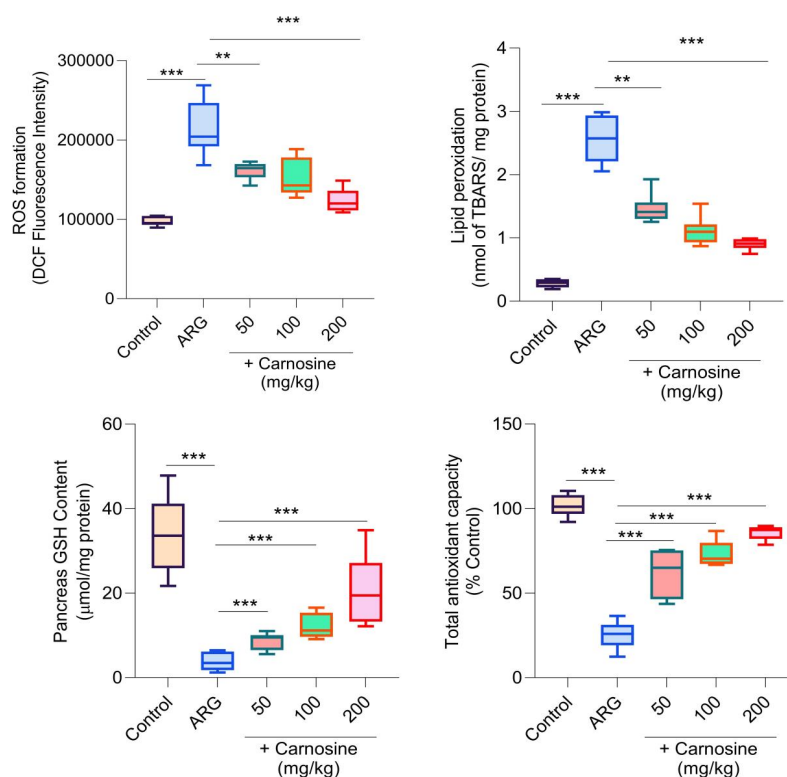


Figure 3. Biomarkers oxidative stress in the pancreas of l-arginine (ARG)-treated mice. ROS: Reactive oxygen species; DCF: 2', 7'-Dichlorodihydrofluorescein; GSH: reduced glutathione. TBARS: Thiobarbituric acid reactive substances. Data are represented as box and whiskers (min to max). Asterisks indicate statistically significant differences (** $P < 0.01$, *** $P < 0.001$).

ure 3). It is important to note that the impact of carnosine on oxidative stress biomarkers in this particular animal model of pancreatitis showed a dose-dependent relationship (Figure 3).

Pancreatic concentrations of pro-inflammatory cytokines (TNF- α , IL-1 β , and IL-6) were markedly elevated in arginine-induced pancreatitis when compared to the con-

trol group (Figure 4). The study revealed that (50, 250, and 500 mg/kg, i.p.) notably reduced TNF- α , IL-1 β , and IL-6 pancreatic levels in mice treated with arginine (Figure 4). The impact of carnosine on pancreatic pro-inflammatory cytokine was dose-dependent in the current study (Figure 4).

In the current animal model of acute pancreatitis, the examination of pancreas tis-

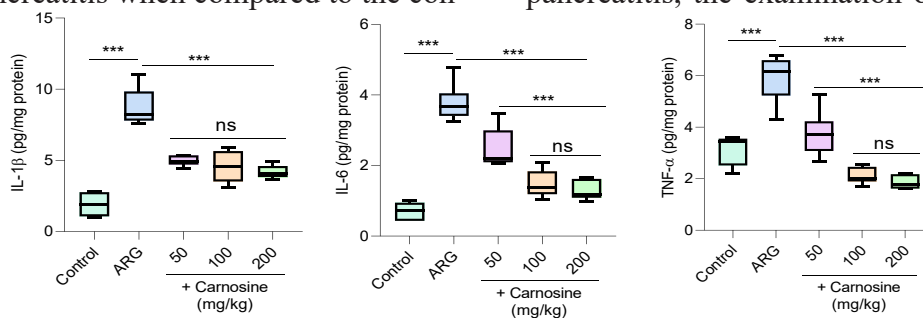


Figure 4. Pancreatic level of pro-inflammatory cytokines in the l-arginine (ARG)-induced pancreatitis animal model. Data are represented as box and whiskers (min to max). Asterisks indicate a statistically significant difference ($P < 0.001$).

Table 1. Grades of pancreas tissue histopathological alterations in an animal model of acute pancreatitis.

Treatment	Acinar Cell Vacuolization	Acinar Cell Necrosis	Inflammation	Total Score
Control	0 (0, 0)	0 (0, 0)	0 (0, 0)	0
ARG	3 (3, 3) *	1 (0, 1) *	3 (2, 3) *	7
ARG + CARN 50 mg/kg	1 (1, 1) #	0 (0, 0) #	1 (1, 1) #	2
ARG + CARN 100 mg/kg	0 (0, 0) #	0 (0, 0) #	1 (1, 1) #	1
ARG + CARN 200 mg/kg	0 (0, 0) #	0 (0, 0) #	1 (0, 1) #	1

0 = absent; 1 = mild; 2 = moderate, and 3 = severe histopathological changes. The histopathological lesions of the pancreas tissue in the current study were scored based on previous investigations in this field (29). ARG: l-arginine; CARN: Carnosine. Data are represented as median and quartiles for six random pictures per group. * Indicates significantly different from the control group ($P < 0.05$). # Indicates significant difference as compared with arginine (ARG)-treated group ($P < 0.05$).

sue from arginine-treated animals showed notable acinar vacuolization, necrosis, and inflammation (Table 1). It was found that carnosine administration significantly decreased pancreas tissue histopathological changes in the current animal model of acute pancreatitis (Table 1).

4. Discussion

Acute pancreatitis (AP) is a severe clinical complication with a high mortality rate. Severe oxidative stress and inflammatory response play a crucial role in the pathogenesis of AP. Unfortunately, there is no specific pharmacological intervention against AP. The current study found that α KG supplementation significantly blunted pancreas tissue injury in an animal model of AP. The effects of α KG on oxidative stress and its associated complications, as well as its role in mitigating pancreas inflammation, seem to play an essential role in its protective properties.

It has been well-established that oxidative stress plays an essential role in the pathogenesis of acute pancreatitis (38-40). It has been found that oxidative stress could induce cellular injury, mitochondrial dysfunction, activation of inflammatory pathways, and impairment of antioxidant defense mechanisms in the pancreas (38). Oxidative stress induces lipid peroxidation, protein oxidation, and DNA damage, contributing to cellular injury and dysfunction in the pancreas tissue during AP (38). In this regard, several studies used

antioxidants to protect pancreas tissue in AP (38). The antioxidant capacity of carnosine is a well-established feature of this peptide (16, 17, 19, 41-43). Carnosine has been shown to possess antioxidative properties through various mechanisms. The radical scavenging activity of carnosine has been mentioned in several studies (44, 45). It has been found that carnosine acts as a direct scavenger of free radicals, including superoxide anion ($O_2^{\bullet-}$), hydroxyl radical (OH^{\bullet}), and peroxy radical (ROO^{\bullet}), as well as reactive nitrogen species (RNS) such as peroxynitrite ($ONOO^-$) (16, 46). By its radical scavenging activity, carnosine neutralizes these free radicals, preventing them from injuring cellular components such as lipids, proteins, and DNA. It has been well-established that carnosine can inhibit lipid peroxidation, a chain reaction that occurs when ROS attacks unsaturated fatty acids in cell membranes, leading to membrane damage and dysfunction (47). By terminating lipid peroxidation chain reactions, carnosine helps preserve the structural integrity and fluidity of cell membranes (47). Carnosine also protects proteins from oxidative damage by scavenging ROS that targets protein side chains, such as reactive carbonyl groups, sulfhydryl groups, and aromatic amino acids (48, 49). The positive effects of carnosine on mitochondrial function, energy metabolism, and alleviation of mitochondria-originated ROS also have been well-established (50-53).

Carnosine can also modulate cellular

redox status by regulating the balance between oxidants and antioxidants within cells. Several studies mentioned that carnosine enhances the activity of endogenous antioxidant enzymes such as glutathione peroxidase (GPx), catalase (CAT), and superoxide dismutase (SOD), which detoxify reactive species (54-56). Additionally, carnosine may influence the expression of antioxidant genes by activating nuclear factor erythroid 2-related factor 2 (Nrf2), a nuclear transcription factor that controls the antioxidant response (54-56).

The antioxidant properties of carnosine were evident in the current study by its effect in mitigating ROS formation and lipid peroxidation and enhancing cellular antioxidant defense in the pancreas tissue of the AP animal model (Figure 3). Hence, a key mechanism of carnosine protective effects in the current study is mediated by its effect on oxidative stress and related complications.

The anti-inflammatory property of carnosine is an interesting feature of this peptide (57, 58). It has been well-established that carnosine could help alleviate inflammation associated with conditions such as arthritis, asthma, and inflammatory bowel disease (59-62). Carnosine has anti-inflammatory effects, possibly modulating the immune response by hindering the production of pro-inflammatory cytokines and chemokines (59, 63). It has been well-characterized that carnosine modulates immune responses by controlling the activity of immune cells such as macrophages, neutrophils, and lymphocytes (64). Carnosine also inhibits the recruitment of inflammatory cells to sites of inflammation (64, 65). Mechanistically, it has been found that carnosine interferes with various signaling pathways involved in inflammation, such as the mitogen-activated protein kinase (MAPK) signaling and the Janus kinase/signal transducer and activator of transcription (JAK/STAT) pathway (66). By inhibiting the activation of these signaling pathways, carnosine blocks the production of inflammatory mediators and reduces inflammation. Regu-

lation of the activity of enzymes involved in inflammation is another interesting feature of carnosine. It has been found that carnosine regulates the activity of enzymes involved in inflammation, such as cyclooxygenase (COX) and lipoxygenase (LOX), which catalyze the production of inflammatory prostaglandins and leukotrienes (67). By inhibiting COX and LOX activity, carnosine reduces the synthesis of pro-inflammatory lipid mediators and attenuates inflammation. All these data mention the potent anti-inflammatory capacity of carnosine. In the current study, we found that carnosine provided significant anti-inflammatory properties in the pancreas tissue in AP model. This peptide significantly decreased pancreas level of proinflammatory cytokines (Figure 4). Moreover, the infiltration of inflammatory cells was significantly suppressed by carnosine in the pancreas tissue (Table 1).

5. Conclusion

In conclusion, the findings of this research indicate that carnosine can be considered a potent agent in combating AP. The impact of this naturally occurring peptide on the inflammatory response, oxidative stress, and related complications is crucial for its protective function in pancreatic tissue. Considering that carnosine is commonly used in humans at high doses (e.g., 1500 mg/day) without any significant adverse effects (68), it can be easily implemented in clinical settings. Therefore, further investigations are warranted to ascertain the efficacy of carnosine in clinical studies targeting AP.

Acknowledgements

This investigation was financially supported by the Vice-Chancellor of Research Affairs of Shiraz University of Medical Sciences (Grant #29661). The authors also thank the Pharmaceutical Sciences Research Center of Shiraz University of Medical Sciences for providing technical facilities to conduct this study.

Authors contributions

Reza Heidari, Mohammad Mehdi Ommati, and Hossein Niknahad conceived the presented idea, developed the theory of the study, verified the analytical methods, and supervised the findings of this work. Heresh Rezaei, Saeed Heidari, Babak Taheri, Forouzan Khodaei, Mohammad Ali Dehghani, Ayeh Rowhanirad, Azadeh Veisi-Goshtasb, and Zahra Honarpishefard contributed to sample preparation, treatments, data collection, and data visualization. Negar Azarpira contributed to histopathological data analysis and visualization. Hossein Niknahad, Reza Heidari, and Mohammad Mehdi Ommati took the lead in

writing the manuscript. Heresh Rezaei prepared the primary draft of the manuscript. All authors discussed the results and contributed to the final version of the manuscript.

Funding source

This study was supported by the "Grant: 29661" from the Vice-Chancellor of Research Affairs, Shiraz University of EMdical Sciences, Shiraz, Iran.

Conflict of Interest

The authors declare that they have no conflict of interest.

References

- Ashraf H, Colombo JP, Marcucci V, Rhoton J, Olowoyo O. A Clinical Overview of Acute and Chronic Pancreatitis: The Medical and Surgical Management. *Cureus*. 2021 Nov 20;13(11):e19764. doi: 10.7759/cureus.19764. PMID: 34938639; PMCID: PMC8684888.
- Klöppel G, Maillet B. Pathology of acute and chronic pancreatitis. *Pancreas*. 1993 Nov;8(6):659-70. doi: 10.1097/00006676-199311000-00001. PMID: 8255882.
- Soti Khiabani M, Mohammadi MS, Gho-reyshy SA, Rohani P, Alimadadi H, Sohoul MH. Acute pancreatitis in 60 Iranian children: do pediatricians follow the new guidelines in diagnosis and management of acute pancreatitis? *BMC Pediatr*. 2022 Jul 29;22(1):457. doi: 10.1186/s12887-022-03509-6. Erratum in: *BMC Pediatr*. 2022 Aug 22;22(1):494. doi: 10.1186/s12887-022-03538-1. PMID: 35906562; PMCID: PMC9336120.
- Wang GJ, Gao CF, Wei D, Wang C, Ding SQ. Acute pancreatitis: etiology and common pathogenesis. *World J Gastroenterol*. 2009 Mar 28;15(12):1427-30. doi: 10.3748/wjg.15.1427. PMID: 19322914; PMCID: PMC2665136.
- Nickel F, Anthony Wise P. Acute pancreatitis and multiple organ failure-Who beats the odds? *United European Gastroenterol J*. 2021 Mar;9(2):137-138. doi: 10.1002/ueg2.12056. PMID: 33871927; PMCID: PMC8259242.
- Thandassery RB, Yadav TD, Dutta U, Appasani S, Singh K, Kochhar R. Dynamic nature of organ failure in severe acute pancreatitis: the impact of persistent and deteriorating organ failure. *HPB (Oxford)*. 2013 Jul;15(7):523-8. doi: 10.1111/j.1477-2574.2012.00613.x. Epub 2012 Dec 5. PMID: 23750495; PMCID: PMC3692022.
- Garg PK, Singh VP. Organ Failure Due to Systemic Injury in Acute Pancreatitis. *Gastroenterology*. 2019 May;156(7):2008-2023. doi: 10.1053/j.gastro.2018.12.041. Epub 2019 Feb 12. PMID: 30768987; PMCID: PMC6486861.
- Manohar M, Verma AK, Venkateshaiah SU, Sanders NL, Mishra A. Pathogenic mechanisms of pancreatitis. *World J Gastrointest Pharmacol Ther*. 2017 Feb 6;8(1):10-25. doi: 10.4292/wjgpt.v8.i1.10. PMID: 28217371; PMCID: PMC5292603.
- Rashid MU, Hussain I, Jehanzeb S, Ullah W, Ali S, Jain AG, Khetsal N, Ahmad S. Pancreatic necrosis: Complications and changing trend of treatment. *World J Gastrointest Surg*. 2019 Apr 27;11(4):198-217. doi: 10.4240/wjgs.v11.i4.198. PMID: 31123558; PMCID: PMC6513789.
- Zerem E. Treatment of severe acute pancreatitis and its complications. *World J Gastroenterol*. 2014 Oct 14;20(38):13879-92. doi: 10.3748/wjg.v20.i38.13879. PMID: 25320523; PMCID: PMC4194569.
- Yang X, Yao L, Fu X, Mukherjee R, Xia Q, Jakubowska MA, Ferdek PE, Huang W. Experimental Acute Pancreatitis Models: History, Current Status, and Role in Translational Research. *Front Physiol*. 2020 Dec 23;11:614591. doi: 10.3389/

fphys.2020.614591. PMID: 33424638; PMCID: PMC7786374.

12. Dawra R, Sharif R, Phillips P, Dudeja V, Dhaulakhandi D, Saluja AK. Development of a new mouse model of acute pancreatitis induced by administration of L-arginine. *Am J Physiol Gastrointest Liver Physiol.* 2007 Apr;292(4):G1009-18. doi: 10.1152/ajpgi.00167.2006. Epub 2006 Dec 14. PMID: 17170029.
13. Mores MG, Fikry EM, El-Gendy AO, Mohamed WR, Badary OA. Probiotics mixture and taurine attenuate L-arginine-induced acute pancreatitis in rats: Impact on transient receptor potential vanilloid-1 (TRPV-1)/IL-33/NF- κ B signaling and apoptosis. *Tissue Cell.* 2023;85:102234. doi: 10.1016/j.tice.2023.102234.
14. Song Y-D, Liu Y-Y, Li D-J, Yang S-J, Wang Q-F, Liu Y-N, Li M-K, Mei C-P, Cui H-N, Chen S-Y, Zhu C-J. Galangin ameliorates severe acute pancreatitis in mice by activating the nuclear factor E2-related factor 2/heme oxygenase 1 pathway. *Biomed Pharmacother.* 2021;144:112293. doi: 10.1016/j.biopha.2021.112293.
15. Siriviriyakul P, Sriko J, Somanawat K, Chayanupatkul M, Klaikeaw N, Werawatganon D. Genistein attenuated oxidative stress, inflammation, and apoptosis in L-arginine induced acute pancreatitis in mice. *BMC Complement Med Ther.* 2022 Aug 4;22(1):208. doi: 10.1186/s12906-022-03689-9. PMID: 35927726; PMCID: PMC9351145.
16. Jukić I, Kolobarić N, Stupin A, Matić A, Kozina N, Mihaljević Z, et al. Carnosine, Small but Mighty-Prospect of Use as Functional Ingredient for Functional Food Formulation. *Antioxidants (Basel).* 2021 Jun 28;10(7):1037. doi: 10.3390/antiox10071037. PMID: 34203479; PMCID: PMC8300828.
17. Boldyrev AA, Aldini G, Derave W. Physiology and pathophysiology of carnosine. *Physiol Rev.* 2013;93:1803-45. doi: 10.1152/physrev.00039.2012.
18. Ommati MM, Jamshidzadeh A, Heidari R, Sun Z, Zamiri MJ, Khodaei F, et al. Carnosine and Histidine Supplementation Blunt Lead-Induced Reproductive Toxicity through Antioxidative and Mitochondria-Dependent Mechanisms. *Biol Trace Elem Res.* 2019 Jan;187(1):151-162. doi: 10.1007/s12011-018-1358-2. Epub 2018 May 16. PMID: 29767280.
19. Caruso G, Di Pietro L, Cardaci V, Maugeri S, Caraci F. The therapeutic potential of carnosine: Focus on cellular and molecular mechanisms. *Curr Res Pharmacol Drug Discov.* 2023 Mar 7;4:100153. doi: 10.1016/j.crphar.2023.100153. PMID: 37441273; PMCID: PMC10333684.
20. Jamshidzadeh A, Heidari R, Latifpour Z, Ommati MM, Abdoli N, Mousavi S, et al. Carnosine ameliorates liver fibrosis and hyperammonemia in cirrhotic rats. *Clin Res Hepatol Gastroenterol.* 2017 Sep;41(4):424-434. doi: 10.1016/j.clinre.2016.12.010. Epub 2017 Mar 7. PMID: 28283328.
21. Jamshidzadeh A, Niknahad H, Heidari R, Zarei M, Ommati MM, Khodaei F. Carnosine protects brain mitochondria under hyperammonemic conditions: Relevance to hepatic encephalopathy treatment. *PharmaNutrition.* 2017;5:58-63. doi: 10.1016/j.phanu.2017.02.004.
22. Ommati MM, Heidari R, Ghanbarinejad V, Aminian A, Abdoli N, Niknahad H. The neuroprotective properties of carnosine in a mouse model of manganese is mediated via mitochondria regulating and antioxidative mechanisms. *Nutr Neurosci.* 2020;23:731-43. doi: 10.1080/1028415X.2018.1552
23. Miceli V, Pampalone M, Frazziano G, Grasso G, Rizzarelli E, Ricordi C, et al. Carnosine protects pancreatic beta cells and islets against oxidative stress damage. *Mol Cell Endocrinol.* 2018;474:105-18. doi: 10.1016/j.mce.2018.02.016.
24. Miceli V, Pampalone M, Frazziano G, Grasso G, Rizzarelli E, Ricordi C, et al. Carnosine protects pancreatic beta cells and islets against oxidative stress damage. *Mol Cell Endocrinol.* 2018 Oct 15;474:105-118. doi: 10.1016/j.mce.2018.02.016. Epub 2018 Feb 26. PMID: 29496567.
25. Saadati S, Kabthymmer RH, Aldini G, Mousa A, Feehan J, de Courten B. Effects of carnosine and histidine-containing dipeptides on biomarkers of inflammation and oxidative stress: a systematic review and meta-analysis. *Nutr Rev.* 2024 Dec 1;82(12):1696-1709. doi: 10.1093/nutrit/nuad150. PMID: 38086332; PMCID: PMC11551452.
26. Ommati MM, Sabouri S, Niknahad H, Arjmand A, Alidaee S, Mazloomi S, et al. Correction to: Pulmonary inflammation, oxidative stress, and fibrosis in a rat model of cholestasis: the po-

- tential protective properties of the dipeptide carnosine. *Naunyn Schmiedebergs Arch Pharmacol*. 2023 Jun;396(6):1337. doi: 10.1007/s00210-023-02463-z. Erratum for: Naunyn Schmiedebergs Arch Pharmacol. 2023 Jun;396(6):1129-1142. doi: 10.1007/s00210-023-02391-y. PMID: 36928558.
27. Percie du Sert N, Hurst V, Ahluwalia A, Alam S, Avey MT, Baker M, et al. The ARRIVE guidelines 2.0: Updated guidelines for reporting animal research. *PLoS Biol*. 2020 Jul 14;18(7):e3000410. doi: 10.1371/journal.pbio.3000410. PMID: 32663219; PMCID: PMC7360023.
28. Ma J, Xiong JY, Hou WW, Yan HJ, Sun Y, Huang SW, et al. Protective effect of carnosine on subcortical ischemic vascular dementia in mice. *CNS Neurosci Ther*. 2012 Sep;18(9):745-53. doi: 10.1111/j.1755-5949.2012.00362.x. PMID: 22943141; PMCID: PMC6493405.
29. Ono N, Horikoshi J, Izawa T, Nishiyama K, Tanaka M, Kuwamura M, et al. L-arginine-induced pancreatitis aggravated by inhibiting Na⁺/Ca²⁺ exchanger 1. *J Vet Med Sci*. 2023 Jun 13;85(6):657-666. doi: 10.1292/jvms.22-0569. Epub 2023 May 23. PMID: 37100607; PMCID: PMC10315542.
30. Heidari R, Niknahad H. The Role and Study of Mitochondrial Impairment and Oxidative Stress in Cholestasis. *Methods Mol Biol*. 2019;1981:117-132. doi: 10.1007/978-1-4939-9420-5_8. PMID: 31016651.
31. Siavashpour A, Khalvati B, Azarpira N, Mohammadi H, Niknahad H, Heidari R. Poly (ADP-Ribose) polymerase-1 (PARP-1) overactivity plays a pathogenic role in bile acids-induced nephrotoxicity in cholestatic rats. *Toxicol Lett*. 2020 May 16;330:144-158. doi: 10.1016/j.toxlet.2020.05.012. Epub ahead of print. PMID: 32422328.
32. Heidari R, Mohammadi H, Ghanbarinejad V, Ahmadi A, Ommati MM, Niknahad H, et al. Proline supplementation mitigates the early stage of liver injury in bile duct ligated rats. *J Basic Clin Physiol Pharmacol*. 2018 Dec 19;30(1):91-101. doi: 10.1515/jbcpp-2017-0221. PMID: 30205645.
33. Heidari R, Rasti M, Shirazi Yeganeh B, Niknahad H, Saedi A, Najibi A. Sulfasalazine-induced renal and hepatic injury in rats and the protective role of taurine. *Bioimpacts*. 2016;6(1):3-8. doi: 10.15171/bi.2016.01. Epub 2016 Mar 28. PMID: 27340618; PMCID: PMC4916549.
34. Irvanpour F, Dargahi L, Rezaei M, Haghani M, Heidari R, Valian N, Ahmadiani A. Intranasal insulin improves mitochondrial function and attenuates motor deficits in a rat 6-OHDA model of Parkinson's disease. *CNS Neurosci Ther*. 2021 Mar;27(3):308-319. doi: 10.1111/cns.13609. Epub 2021 Jan 26. PMID: 33497031; PMCID: PMC7871791.
35. Heidari R, Jamshidzadeh A, Ghanbarinejad V, Ommati MM, Niknahad H. Taurine supplementation abates cirrhosis-associated locomotor dysfunction. *Clin Exp Hepatol*. 2018 Jun;4(2):72-82. doi: 10.5114/ceh.2018.75956. Epub 2018 May 25. PMID: 29904723; PMCID: PMC6000746.
36. Shafiekhani M, Ommati MM, Azarpira N, Heidari R, Salarian AA. Glycine supplementation mitigates lead-induced renal injury in mice. *J Exp Pharmacol*. 2019 Feb 18;11:15-22. doi: 10.2147/JEP.S190846. PMID: 30858736; PMCID: PMC6385776.
37. Ahmadi A, Niknahad H, Li H, Mobasheri A, Manthari RK, Azarpira N, et al. Corrigendum to "The inhibition of NFκB signaling and inflammatory response as a strategy for blunting bile acid-induced hepatic and renal toxicity" [Toxicol. Lett. 349 (2021)12 - 29]. *Toxicol Lett*. 2022 Jan 1;354:65. doi: 10.1016/j.toxlet.2021.07.006. Epub 2021 Nov 11. Erratum for: Toxicol Lett. 2021 Oct 1;349:12-29. doi: 10.1016/j.toxlet.2021.05.012. PMID: 34774364.
38. Robles L, Vaziri ND, Ichii H. Role of Oxidative Stress in the Pathogenesis of Pancreatitis: Effect of Antioxidant Therapy. *Pancreat Disord Ther*. 2013 Apr 1;3(1):112. doi: 10.4172/2165-7092.1000112. PMID: 24808987; PMCID: PMC4009983.
39. Pădureanu V, Florescu DN, Pădureanu R, Ghenea AE, Gheonea DI, Oancea CN. Role of antioxidants and oxidative stress in the evolution of acute pancreatitis (Review). *Exp Ther Med*. 2022 Mar;23(3):197. doi: 10.3892/etm.2022.11120. Epub 2022 Jan 5. PMID: 35126700; PMCID: PMC8794551.
40. Sweiry JH, Mann GE. Role of oxidative stress in the pathogenesis of acute pancreatitis. *Scand J Gastroenterol Suppl*. 1996;219:10-5. doi: 10.3109/00365529609104992. PMID: 8865464.
41. Ommati MM, Farshad O, Ghanbarinejad V, Mohammadi HR, Khadijeh M, Negar A, et al.

The Nephroprotective Role of Carnosine Against Ifosfamide-Induced Renal Injury and Electrolytes Imbalance is Mediated Via the Regulation of Mitochondrial Function and Alleviation of Oxidative Stress. *Drug Res (Stuttg)*. 2020 Jan;70(1):49-56. doi: 10.1055/a-1017-5085. Epub 2019 Oct 31. PMID: 31671464.

42. Farshad O, Ommati MM, Yüzügülen J, Jamshidzadeh A, Mousavi K, Ahmadi Z, et al. Carnosine mitigates biomarkers of oxidative stress, improves mitochondrial function, and alleviates histopathological alterations in the renal tissue of cholestatic rats. *Pharm Sci*. 2020;27;32-45. doi: 10.34172/PS.2020.60.

43. Jamshidzadeh A, Abdoli N, Niknahad H, Azarpira N, Mousavi S, Mardani E, et al. Carnosine supplementation mitigates brain tissue markers of oxidative stress in a rat model of fulminant hepatic failure. *Trend Pharm Sci*. 2017;3;149-60. doi: 10.1111/tips.v3i3.149.

44. Guiotto A, Calderan A, Ruzza P, Borin G. Carnosine and carnosine-related antioxidants: a review. *Curr Med Chem*. 2005;12(20):2293-315. doi: 10.2174/0929867054864796. PMID: 16181134.

45. Salim-Hanna M, Lissi E, Videla LA. Free radical scavenging activity of carnosine. *Free Radic Res Commun*. 1991;14(4):263-70. doi: 10.3109/10715769109088955. PMID: 1651887.

46. Aldini G, Facino RM, Beretta G, Carini M. Carnosine and related dipeptides as quenchers of reactive carbonyl species: from structural studies to therapeutic perspectives. *Biofactors*. 2005;24(1-4):77-87. doi: 10.1002/biof.5520240109. PMID: 16403966.

47. Zhao J, Posa DK, Kumar V, Hoetker D, Kumar A, Ganesan S, Riggs DW, Bhatnagar A, Wempe MF, Baba SP. Carnosine protects cardiac myocytes against lipid peroxidation products. *Amino Acids*. 2019 Jan;51(1):123-138. doi: 10.1007/s00726-018-2676-6. Epub 2018 Nov 17. PMID: 30449006; PMCID: PMC6377314.

48. Nagasawa T, Yonekura T, Nishizawa N, Kitts DD. In vitro and in vivo inhibition of muscle lipid and protein oxidation by carnosine. *Mol Cell Biochem*. 2001 Sep;225(1-):29-34. doi: 10.1023/a:1012256521840. PMID: 11716361.

49. Jamshidzadeh A, Heidari R, Abazari F, Ramezani M, Khodaei F, Ommati MM, et al. Antimalarial drugs-induced hepatic injury in rats

and the protective role of carnosine. *Pharm Sci*. 2016;22;170-80. doi: 10.15171/PS.2016.27.

50. Heidari R, Ghanbarinejad V, Ommati MM, Jamshidzadeh A, Niknahad H. Regulation of mitochondrial function and energy metabolism: A primary mechanism of cytoprotection provided by carnosine. *Trend Pharm Sci*. 2018;4. doi.

51. Heidari R, Abdoli N, Ommati MM, Jamshidzadeh A, Niknahad H. Mitochondrial impairment induced by chenodeoxycholic acid: The protective effect of taurine and carnosine supplementation. *Trend Pharm Sci*. 2018;4;29-42. doi: 10.1111/tips.v4i2.182.

52. Eftekhari A, Heidari R, Ahmadian E, Eghbal MA. Cytoprotective properties of carnosine against isoniazid-induced toxicity in primary cultured rat hepatocytes. *Pharm Sci*. 2018;24;257-63. doi: 10.15171/PS.2018.38.

53. Ghanbarinejad V, Ahmadi A, Niknahad H, Ommati MM, Heidari R. Carnosine mitigates manganese mitotoxicity in an in vitro model of isolated brain mitochondria. *Adv Pharm Bull*. 2019;9;294-301. doi: 10.15171/apb.2019.034.

54. Zhou JY, Lin HL, Qin YC, Li XG, Gao CQ, Yan HC, et al. l-Carnosine Protects Against Deoxynivalenol-Induced Oxidative Stress in Intestinal Stem Cells by Regulating the Keap1/Nrf2 Signaling Pathway. *Mol Nutr Food Res*. 2021 Sep;65(17):e2100406. doi: 10.1002/mnfr.202100406. Epub 2021 Jul 11. PMID: 34216418.

55. Busa P, Lee SO, Huang N, Kuthati Y, Wong CS. Carnosine Alleviates Knee Osteoarthritis and Promotes Synoviocyte Protection via Activating the Nrf2/HO-1 Signaling Pathway: An In-Vivo and In-Vitro Study. *Antioxidants (Basel)*. 2022 Jun 20;11(6):1209. doi: 10.3390/antiox11061209. PMID: 35740105; PMCID: PMC9220310.

56. Aldini G, de Courten B, Regazzoni L, Gilardoni E, Ferrario G, Baron G, Altomare A, D'Amato A, Vistoli G, Carini M. Understanding the antioxidant and carbonyl sequestering activity of carnosine: direct and indirect mechanisms. *Free Radic Res*. 2021 Apr;55(4):321-330. doi: 10.1080/10715762.2020.1856830. Epub 2020 Dec 11. PMID: 33302741.

57. Calabrese V, Scuto M, Salinaro AT, Dionisio G, Modafferi S, Ontario ML, Greco V, Sciuto S, Schmitt CP, Calabrese EJ, Peters V. Hydrogen Sulfide and Carnosine: Modulation of Oxidative

Stress and Inflammation in Kidney and Brain Axis. *Antioxidants (Basel)*. 2020 Dec 18;9(12):1303. doi: 10.3390/antiox9121303. PMID: 33353117; PMCID: PMC7767317.

58. Solana-Manrique C, Sanz FJ, Martínez-Carrión G, Paricio N. Antioxidant and Neuroprotective Effects of Carnosine: Therapeutic Implications in Neurodegenerative Diseases. *Antioxidants (Basel)*. 2022 Apr 26;11(5):848. doi: 10.3390/antiox11050848.

59. Son DO, Satsu H, Kiso Y, Totsuka M, Shimizu M. Inhibitory effect of carnosine on interleukin-8 production in intestinal epithelial cells through translational regulation. *Cytokine*. 2008 May;42(2):265-276. doi: 10.1016/j.cyto.2008.02.011. Epub 2008 Apr 7. PMID: 18397832.

60. Tanaka KI, Kawahara M. Carnosine and Lung Disease. *Curr Med Chem*. 2020;27(11):1714-1725. doi: 10.2174/0929867326666190712140545. PMID: 31309876.

61. Ponist S, Drafi F, Kuncirova V, Mihalova D, Rackova L, Danisovic L, et al. Effect of Carnosine in Experimental Arthritis and on Primary Culture Chondrocytes. *Oxid Med Cell Longev*. 2016;2016:8470589. doi: 10.1155/2016/8470589. Epub 2016 Jan 17. PMID: 26885252; PMCID: PMC4739233.

62. Impellizzeri D, Siracusa R, Cordaro M, Peritore AF, Gugliandolo E, D'amico R, et al. Protective effect of a new hyaluronic acid-carnosine conjugate on the modulation of the inflammatory response in mice subjected to collagen-induced arthritis. *Biomed Pharmacother*. 2020 May;125:110023. doi: 10.1016/j.biopha.2020.110023. Epub 2020 Feb 25. PMID: 32092830.

63. Caruso G, Fresta CG, Fidilio A, O'Donnell F, Musso N, Lazzarino G, et al. Carnosine De-

creases PMA-Induced Oxidative Stress and Inflammation in Murine Macrophages. *Antioxidants (Basel)*. 2019 Aug 6;8(8):281. doi: 10.3390/antiox8080281. PMID: 31390749; PMCID: PMC6720685.

64. Fresta CG, Fidilio A, Lazzarino G, Musso N, Grasso M, Merlo S, et al. Modulation of Pro-Oxidant and Pro-Inflammatory Activities of M1 Macrophages by the Natural Dipeptide Carnosine. *Int J Mol Sci*. 2020 Jan 25;21(3):776. doi: 10.3390/ijms21030776. PMID: 31991717; PMCID: PMC7038063.

65. Ooi TC, Chan KM, Sharif R. Zinc Carnosine Inhibits Lipopolysaccharide-Induced Inflammatory Mediators by Suppressing NF- κ b Activation in Raw 264.7 Macrophages, Independent of the MAPKs Signaling Pathway. *Biol Trace Elem Res*. 2016 Aug;172(2):458-464. doi: 10.1007/s12011-015-0615-x. Epub 2016 Jan 9. PMID: 26749414.

66. Zhu W, Ren L, Zhang L, Qiao Q, Farooq MZ, Xu Q. The Potential of Food Protein-Derived Bioactive Peptides against Chronic Intestinal Inflammation. *Mediators Inflamm*. 2020 Sep 9;2020:6817156. doi: 10.1155/2020/6817156. PMID: 32963495; PMCID: PMC7499337.

67. Choi HS, Kim ES, Keum B, Chun HJ, Sung MK. L-carnosine and zinc in gastric protection. In *Betaine: Chemistry, Analysis, Function and Effects*. 8 ed. Vol. 2015-January. *Royal Society of Chemistry*. 2015. p. 548-565. (Food and Nutritional Components in Focus; 8). doi: 10.1039/9781782622611-00548

68. Cesak O, Vostalova J, Vidlar A, Bastlova P, Student V Jr. Carnosine and Beta-Alanine Supplementation in Human Medicine: Narrative Review and Critical Assessment. *Nutrients*. 2023 Apr 5;15(7):1770. doi: 10.3390/nu15071770. PMID: 37049610; PMCID: PMC10096773.

