

Evaluating the effects of different fractions obtained from *Gundelia tournefortii* extract against carbon tetrachloride-induced liver injury in rats

Hossein Niknahad^{1,2}, Reza Heidari^{1,*}, Tannaz Mokhtebaz³, Sasan Mansouri³, Shadab Dehshahri⁴, Narges Abdoli⁵, Negar Azarpira⁶, Asma Najibi²

¹Pharmaceutical Sciences Research Center, Shiraz University of Medical Sciences, Shiraz, Iran.

²Department of Pharmacology and Toxicology, School of Pharmacy, Shiraz University of Medical Sciences, Shiraz, Iran.

³Student Research Committee, International branch, Shiraz University of Medical Sciences, Shiraz, Iran.

⁴Department of Pharmacognosy, School of Pharmacy, Shiraz University of Medical Sciences, International Branch, Shiraz, Iran.

⁵Food and Drug Organization, Ministry of Health, Tehran, Iran.

⁶Transplant Research Center, Shiraz University of Medical Sciences, Shiraz, Iran.

Abstract

Xenobiotics-induced liver injury is a major challenge for clinicians and pharmaceutical industry. Hence, finding new therapeutic molecules against this complication has clinical value. The current investigation aimed to evaluate the potential protective effects of different fractions obtained from *Gundelia tournefortii* (GT) hydroalcoholic extract in a rat model of acute hepatic injury. Male Sprague-Dawley rats (200-250 g) were treated with carbon tetrachloride (CCl₄) (1.5 ml/kg, i.p). Then ethanol, water, chloroform, ethyl acetate, and n-Butanol fractions of GT extract were administered. Biochemical and histopathological markers of hepatic injury were assessed, and glutathione (GSH) and lipid peroxidation were monitored in liver samples. CCl₄ administration caused hepatotoxicity as revealed by an increase in serum alanine aminotransferase (ALT), aspartate aminotransferase (AST), and lactate dehydrogenase (LDH) activity, as well as pathological changes of the liver. Furthermore, a significant reduction in hepatic glutathione content and an elevation in lipid peroxidation were observed in CCl₄ treated rats. It was found that the n-butanol (200 mg/kg) and the ethyl acetate (300 mg/kg) fractions of GT extract protected liver against CCl₄ induced damage as judged by lower AST, ALT, LDH and lipid peroxidation, prevention of tissue glutathione depletion, and alleviation of histopathological damages of liver in the extract treated animals. As n-butanol and the ethyl acetate fractions of GT effectively alleviated the liver injury induced by CCl₄ and provided antioxidant properties, we might be able to propose that the hepatoprotective chemicals of GT extract are present in these fractions.

Keywords: *Gundelia tournefortii*, Hepatoprotective, Hepatotoxicity, Liver injury, Medicinal plants.

1. Introduction

Many chemicals are able to affect liver function. Indeed, the hepatic injury is a major clinical problem induced by different xenobiotics including drugs and other chemicals (1-4). Hence, finding new protective agents against chemicals-induced hepatic injury has clinical value. Several

hepatoprotective agents are studied to find a way to protect the liver from toxic insults (5-7). Recently, interest in the discovery of natural hepatoprotective agents has risen greatly. Principal candidates in this discovery process are medicinal plants (8).

Carbon tetrachloride (CCl₄)-induced liver injury is extensively applied as an animal model of liver fibrosis and hepatic failure (9). Extensive reactive oxygen species (ROS) formation and its deleterious adverse events that finally lead to he-

Corresponding Author: Reza Heidari, Pharmaceutical Sciences Research Center, Shiraz University of Medical Sciences, Shiraz, Iran. Email: Rezaheidari@hotmail.com

patic failure, are common futures ensued CCl₄ administration to animals (9). The hepatoprotective properties of many herbal remedies have been evaluated in this model to find hepatoprotective molecules with potential therapeutic capabilities (10-13).

Gundelia tournefortii (L.) (GT), which is known as “Kangar” in Iran, is used as food in different forms. Furthermore, this plant is used against gastrointestinal disease in Iranian folk medicine (14-16). Previously, we have shown that the hydroalcoholic extract of GT effectively alleviated carbon tetrachloride-induced toxicity in both isolated hepatocytes and animals (17). However, it was found that the concentrations greater than 1 mg/ml of GT extract were cytotoxic in isolated rat hepatocytes (17). The exact chemical(s) responsible for the hepatoprotective effects of GT extract is not fully understood so far. The current investigation attempted to evaluate the hepatoprotective effects of different fractions obtained from the hydroalcoholic extract of *G. tournefortii*, which will enhance our understanding about the types of chemicals responsible for the hepatoprotective properties of this plant.

2. Materials and methods

2.1. Chemicals

Trichloroacetic acid (TCA), Dithio-bis-nitro benzoic acid (DTNB), Phosphoric acid, n-Butanol, and Carbon tetrachloride (CCl₄), were purchased from Merck (Darmstadt, Germany). Thiobarbituric acid (TBA), and Tris (hydroxymethyl) aminomethane), were from Sigma Chemical Company Sigma-Aldrich (St. Louis, USA). Kits for evaluation of serum markers of liver injury were obtained from Pars Azmun[®] (Tehran, Iran). All other chemicals used for buffer solutions were of the highest grade commercially available.

2.2. Plant material and extracts preparation

Fresh footstalk of GT was collected during April 2013 from rural areas around Shiraz, Fars, Iran. The plant was authenticated by a botanist and the voucher specimen with code “34500” has been deposited. Six hundred and forty grams of dried powdered plant were macerated in 70% aqueous ethanol at room temperature for 48 h. The

extract was filtered and concentrated under reduced pressure and low temperature (40 °C) on a rotary evaporator until no ethanol remained in the extract. The prepared extract was dispersed in 200 ml water and placed in a decanter. Several solvents with different polarities, including ethanol, water, chloroform, ethyl acetate, and n-Butanol (600 mL each), were used to prepare different fractions of GT extract. The obtained fractions were concentrated on a rotary evaporator and then stored in 4° C until administration.

2.3. Animals and Study Procedure

Male Sprague-Dawley rats (200-250 g) were obtained from the animal laboratories of Shiraz University of Medical Sciences, Shiraz, Iran. Animals had free access to standard laboratory chow and tap water. Rats were handled and used, according to the ethical guidelines of Shiraz University of Medical Sciences, Shiraz, Iran. Rats were randomly divided into thirteen groups of six animals. The treatments were as follows:

- 1) Control (vehicle-treated, received olive oil, 1.5 ml/kg, i.p)
- 2) CCl₄ (1.5 ml/kg in olive oil, i.p)
- 3) CCl₄+n-Hexane fraction (200 mg/kg, gavage)
- 4) CCl₄+n-Hexane fraction (300 mg/kg, gavage)
- 5) CCl₄+Ethanol fraction (200 mg/kg, gavage)
- 6) CCl₄+Ethanol fraction (300 mg/kg, gavage.)
- 7) CCl₄+Ethylacetate fraction (200 mg/kg, gavage)
- 8) CCl₄+Ethylacetate fraction (300 mg/kg, gavage)
- 9) CCl₄+Chloroform fraction (200 mg/kg, gavage)
- 10) CCl₄+Chloroform fraction (300 mg/kg, gavage)
- 11) CCl₄+Water fraction (200 mg/kg, gavage)
- 12) CCl₄+Water fraction (300 mg/kg, gavage)
- 13) CCl₄+Silymarin (25 mg/kg, gavage)

The hepatotoxic dose of CCl₄ in rats was selected from previous investigations (18). Different fractions of GT extract were compared with silymarin as a proved hepatoprotective agent against CCl₄-induced liver injury (19, 20). The extracts were administered orally to rats for three consecutive days before administration of CCl₄. Twenty-four hours after CCl₄ administration, animals were anesthetized by pentobarbital (50 mg/kg, i.p), and blood was col-

lected from the vena cava. The liver was carefully dissected and washed in cold normal saline.

2.4. Serum biochemical analysis and liver histopathology

Blood was collected from the abdominal vena cava under pentobarbital anesthesia, and the liver was removed. The blood was allowed to clot at 25 °C, and serum was prepared by centrifugation (1000 g, for 20 min). Serum alanine aminotransferase (ALT), aspartate aminotransferase (AST), and lactate dehydrogenase (LDH) activities were measured with commercial kits (21-23). For histopathological evaluation, samples of liver were fixed in buffered formalin solution (0.4% sodium phosphate monobasic, NaH₂PO₄, 0.64% sodium phosphate dibasic, Na₂HPO₄, and 10% formaldehyde in distilled water). Paraffin embedded sections of liver were prepared and stained with haematoxylin and eosin (H&E) before light microscope viewing (22, 24).

2.5. Liver glutathione content measurement

Liver glutathione contents were assessed by determining non-protein sulphhydryls with the Ellman reagent (25). Samples of the liver (200 mg) were homogenized in 8 ml of 20 mM EDTA. Then, 5 mL of tissue homogenate was mixed with 4 mL of distilled water and 1 mL of trichloroacetic acid (TCA) (50% w/v) (26). The mixture was vigorously shaken and centrifuged (15 min, 700 g, 4 °C). Then, 2 mL of the supernatant was treated with 100 µl of Ellman reagent (DTNB, 0.01M in methanol), and the absorbance of developed color was measured at 412 nm with an Ultrospec 2000[®] UV spectrophotometer (23, 27-28).

2.6. Lipid peroxidation assay

Thiobarbituric acid reactive substances (TBARS) test was employed to assess the amount of lipid peroxidation in liver tissue. Briefly, the reaction mixture consists of 0.5 mL of 10% liver homogenate, 3 mL of 1% phosphoric acid, and 1 mL of 1% thiobarbituric acid. The mixture was shaken and then heated in boiling water (100 °C) for 45 min (21, 23, 29). Samples were centrifuged

Table 1. The effect of different fractions of *Gundelia tournefortii* extracts on serum biochemical parameters after CCl₄ administration to rats.

Treatment	Parameters assessed		
	Serum ALT (U/l)	Serum AST (U/l)	Serum LDH (U/l)
Control (Vehicle-treated)	50.25±4	123±2.35	993±3
+Carbon tetrachloride (CCl ₄)	4499±1314*	4984±723*	10464±2269*
+SLM 25 mg/kg	135.2±15 ^a	451±53 ^a	2250±226 ^a
+EF. 200 mg/kg	1548±680 ^a	2082±475 ^a	2328±414 ^a
+EF. 300 mg/kg	195±48 ^a	342±66 ^a	1388±116 ^a
+CF. 200 mg/kg	1906±440	3805±817	6056±2770
+CF. 300 mg/kg	3214±794	3499±906	2633±1217 ^a
+EAF. 200 mg/kg	2828±760 ^a	2612±683 ^a	4168±1165 ^a
+EAF. 300 mg/kg	793±410 ^a	1097±709 ^a	2601±478 ^a
+BF. 200 mg/kg	1131±68 ^a	1401±363 ^a	2011±189 ^a
+BF. 300 mg/kg	663±182 ^a	836±213 ^a	1492±52 ^a
+WF. 200 mg/kg	3899±1190	5732±1262	11608±3486
+WF. 300 mg/kg	2598±907	3816±908	8364±4459

Data are presented as Mean±SD for 6 animals in each group.

* Indicates significantly higher than control (Vehicle-treated) group ($P<0.001$).

^a Indicates significantly lower as compared with carbon tetrachloride-treated rats ($P<0.001$).

SLM; Silymarin, EF: Ethanol fraction, CF: Chloroform fraction, EAF: Ethylacetate fraction, BF: n-butanol fraction, WF: Water fraction.

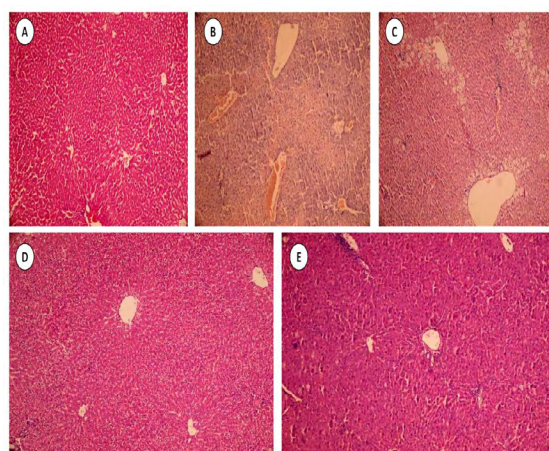


Figure 1. Effects of hydroalcoholic (Ethanolic) extract of GT on carbon tetrachloride-induced liver injury in the rat. For histopathologic changes grades refer to table 3. **A:** Normal liver histopathology obtained from control (Vehicle-treated group) showed no significant changes of liver architecture. **B&C:** Centrilobular necrosis, fatty changes, and inflammatory cells infiltration were observed in the liver of CCl₄-treated animals. **D&E:** Hydroalcoholic extract of GT (200&300 mg/kg respectively) alleviated liver histopathological changes induced by CCl₄ (Table 3).

(3000 g for 5 minutes) and the absorbance of developed color was read at 532 nm using an Ultrospec 2000[®] UV spectrophotometer (29).

2.7. Statistical analysis

Results are shown as Mean±SEM for at least six animals in each group. Comparisons between multiple groups were made by a one-way

Table 2. Liver glutathione (GSH) content and tissue lipid peroxidation after administration of carbon tetrachloride and different fractions obtained from GT extract.

	Parameters assessed	
	Hepatic Glutathione ($\mu\text{mol}/\text{mg}$ tissue)	Lipid Peroxidation (nmol/mg tissue)
Control (Vehicle-treated)	56.3±2.24	1.92±0.22
+Carbon tetrachloride (CCl ₄)	21±1.2 ^c	7.95±1 ^a
+SLM 25 mg/kg	32±0.6 ^d	5.48±0.47 ^b
+EF. 200 mg/kg	32±2.5 ^d	3.79±0.22 ^b
+EF. 300 mg/kg	33±1.16 ^d	4.05±0.14 ^b
+CF. 200 mg/kg	23.2±2.73	8.03±0.26
+CF. 300 mg/kg	28.6±1.3	7.2±0.83
+EAF. 200 mg/kg	39.88±2 ^d	6.4±0.5 ^b
+EAF. 300 mg/kg	40.87±1 ^d	6±0.62 ^b
+BF. 200 mg/kg	43.7±1.97 ^d	6.98±1.1 ^b
+BF. 300 mg/kg	49.3±4.72 ^d	5.21±0.8 ^b
+WF. 200 mg/kg	20.8±1.25	8±0.42
+WF. 300 mg/kg	21.72±1.7	7.52±0.67

Data are presented as Mean±SEM (n=6).

^aIndicates significantly higher than control (Vehicle-treated) group ($P<0.05$).

^bIndicates significantly lower as compared carbon tetrachloride-treated rats ($P<0.05$).

^cIndicates significantly lower as compared with control animals ($P<0.05$).

^dIndicates significantly higher as compared carbon tetrachloride-treated rats ($P<0.05$).

SLM; Silymarin, **EF:** Ethanol fraction, **CF:** Chloroform fraction, **EAF:** Ethylacetate fraction, **BF:** n-butanol fraction, **WF:** Water fraction.

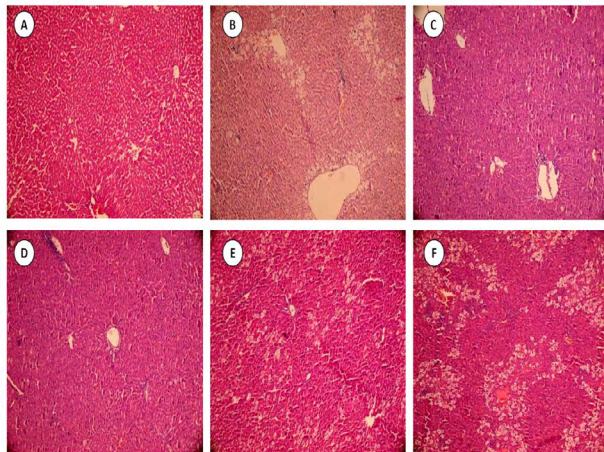


Figure 2. Effects of ethyl acetate and n-butanol fractions of GT extract on carbon tetrachloride-induced liver injury in rats. For histopathologic changes grades refer to table 3. **A:**Control (vehicle-treated) group, showed normal liver histopathology. **B:**Centrilobular necrosis, fatty changes, and inflammatory cells infiltration were observed in the liver of CCl_4 -treated animals. **C&D:**Administration of the ethyl acetate fraction of GT extract (200 and 300 mg/kg respectively) alleviated histopathological changes of liver induced by CCl_4 . **E&F:** n-butanol fraction of GT extract (200 and 300 mg/kg respectively) reduced histopathological lesions induced by CCl_4 . The n-butanol fraction was most effective at a lower dose (200 mg/kg, E) (Table 3).

analysis of variance (ANOVA) followed by Turkey's post hoc test. Differences were considered significant when $P < 0.05$.

3. Results

CCl_4 (1.5 ml/kg, i.p) caused severe hepatic injury in rats as revealed by a dramatic increase in serum biomarkers of liver injury. It was found that serum ALT, AST, and LDH were significantly higher in CCl_4 -treated rats than in the control group (Table 1). Moreover, hepatic glutathione (GSH) contents were decreased and significant lip-

id peroxidation was detected in the liver of CCl_4 -treated animals (Table 2). Liver histopathological evaluation of CCl_4 treated rats showed centrilobular necrosis, fatty changes, and inflammatory cells infiltration (Figure 1, parts B&C).

Different fractions obtained from the hydroalcoholic extract of GT were screened for their possible hepatoprotective activity against CCl_4 in rats. It was found that ethyl acetate and n-butanol fractions of GT hydroalcoholic extract, effectively reduced serum biochemical markers of liver injury (Table 1). The water and chloroform fractions

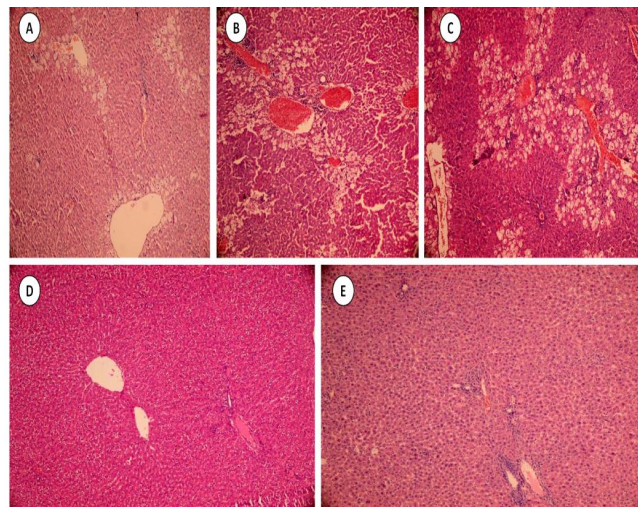


Figure 3. Effects of chloroform and water fractions of GT extract on carbon tetrachloride-induced liver injury in the rat. For histopathologic changes grades refer to table 3. Centrilobular necrosis, fatty changes, and inflammatory cells infiltration were observed in the liver of CCl_4 -treated animals (**A**). Administration of the chloroform fraction (**B&C**:200 mg/kg and 300 mg/kg respectively) and/or water fraction (**D&E**:200 mg/kg and 300 mg/kg respectively) of GT extract didn't alleviate pathological lesions induced by CCl_4 (Table 3).

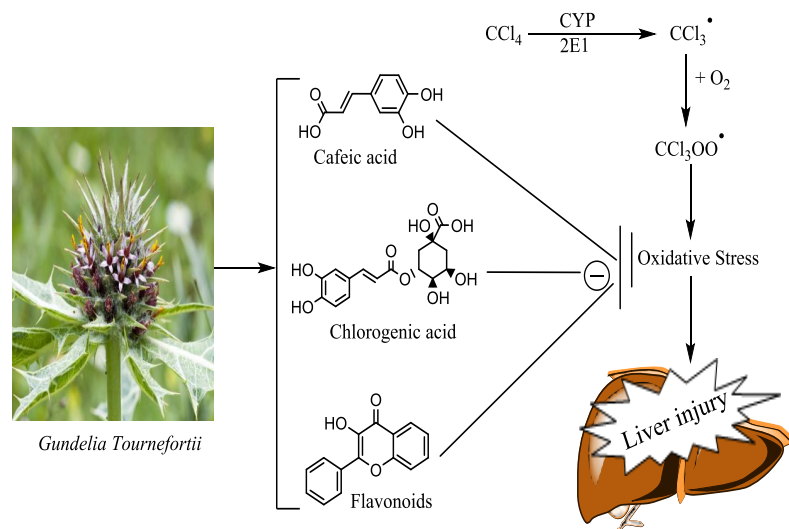


Figure 4. The proposed mechanisms of hepatoprotection provided by GT. Different chemicals present in GT extract might counteract CCl_4 -induced oxidative stress and its deleterious consequences (The *Gundelia tournefortii* picture was obtained from https://commons.wikimedia.org/wiki/File:Gundelia_tournefortii_-_Gundelia_01.jpg). CYP2E1: Cytochrome P₄₅₀2E1.

couldn't reduce ALT, AST, and LDH in the serum of CCl_4 -treated rats (Table 1).

A lower amount of lipid peroxidation was detected in the liver of animals that were co-treated with n-butanol and/or ethyl acetate fractions of GT extract (Table 2). Moreover, these fractions prevented the decrease in liver GSH induced by CCl_4 (Table 2). Water and chloroform fractions of GT extract didn't have any significant effect on the level of liver glutathione and/or lipid peroxidation in CCl_4 -treated animals (Table 2).

It was found that ethyl acetate (Figure 2) and n-butanol (Figure 3) fractions of GT extract effectively ameliorated CCl_4 -induced histopathological changes of the liver. Water and chloroform fractions of GT extract were unable to prevent CCl_4 induced histopathological lesions (Figure 4).

4. Discussion

Carbon tetrachloride-induced hepatic injury is a widely employed experimental model to study the effects of hepatoprotective agents (30-32). CCl_4 is metabolized by liver cytochrome P₄₅₀ (CYP₄₅₀) system to produce a highly reactive intermediate, which can start a chain of free radical formation resulting in peroxidation of biomembrane lipids and damage to proteins and other cell components, which may eventually lead to hepatic injury (33). Hence, the major mechanism involved in the liver injury induced by CCl_4 is believed to

be oxidative stress induction and its subsequent events including GSH depletion and lipid peroxidation (34) (Figure 4).

In this study, CCl_4 caused an elevation in serum biomarkers of liver injury and histopathological changes in rat liver. Moreover, CCl_4 also decreased the hepatic glutathione reservoirs and increased lipid peroxidation in the liver. These changes indicate the occurrence of oxidative stress following CCl_4 administration to rats. The n-butanol fraction with doses of 200, and 300 mg/kg and the ethyl acetate fraction with the dose of 300 mg/kg, protected the rat liver against CCl_4 induced injury. As the oxidative stress plays an important role in CCl_4 -induced liver injury (20), a part of the hepatoprotective mechanism of GT might be related to its antioxidant properties. Different chemicals are characterized in GT. Compounds such as phenolic acids and flavonoids (35, 36), caffeic acid and its derivatives (37), chlorogenic acid (38), saffrole, and curcumin (36) are identified in GT (Figure 4). Different previous investigations on the same species such as *Cynara scolymus* L. and *Silybum marianum* L., revealed that their hepatoprotective effects were mainly due to their antioxidant content (39, 40) and silymarin, as a widely investigated hepatoprotective agent (32).

There is a large circumstantial evidence implicating the hepatoprotective properties of flavonoids (41, 42), chlorogenic acid (43), and

caffeic acid and its derivatives (44). Moreover, other polyphenols such as quercetin, gallic acid, and curcumin effectively prevented CCl₄ induced liver injury in previous investigations (45, 46) (47, 48). Hence, these chemicals might be responsible for hepatoprotective effects of GT extract (Figure 4). These compounds might distribute in different fractions of GT extract due to their polarity. Therefore, different hepatoprotective profiles are observed by administration of these fractions.

As mentioned, lipid peroxidation is one of the most prominent events occurred after oxidative stress in biological systems (49). The chemicals of GT extract have been proven to counteract lipid peroxidation in liver (43, 44). On the other hand, glutathione is a key component in the regulation of cellular homeostasis (50). The hepatoprotective fractions (n-butanol and ethyl acetate fractions) of GT hydroalcoholic extract in the current investigation, preserved hepatic glutathione stores and decreased lipid peroxidation in the liver. Some investigations proposed the role of natural products in inhibiting CYP2E1 and blocking CCl₄ bioactivation (51). Although not investigated yet, such mechanism might also be involved in the hepatoprotective properties of the GT extract constituents.

5. References

1. Lee WM. Drug-induced hepatotoxicity. *New Eng J Med*. 2003;349:474-85.
2. Abdoli N, Heidari R, Azarmi Y, Eghbal MA. Mechanisms of the Statins Cytotoxicity in Freshly Isolated Rat Hepatocytes. *J Biochem Mol Toxicol*. 2013;27:287-94.
3. Heidari R, Niknahad H, Jamshidzadeh A, Eghbal MA, Abdoli N. An Overview on the Proposed Mechanisms of Antithyroid Drugs-Induced Liver Injury. *Adv Pharm Bull*. 2015;5:1-11.
4. Heidari R, Niknahad H, Jamshidzadeh A, Abdoli N. Factors affecting drug-induced liver injury: antithyroid drugs as instances. *Clin Mol Hepatol*. 2014;20:237-48.
5. Yilmaz O, Ersan Y, Ozsahin AD, Ozturk AI, Ozkan Y. Consequences of the Combined α -tocopherol, Ascorbic Acid and α -lipoic Acid on the Glutathione, Cholesterol and Fatty Acid Composition in Muscle and Liver of Diabetic Rats. *Iran J Bas Med Sci*. 2013;16:165-72.

Collectively, it is proposed that the hepatoprotective effects of GT extract might be attributed to the presence of protective compounds, such as caffeic acid, chlorogenic acid, and different flavonoids (Figure 4) (39, 40). These compounds have different physicochemical properties and might distribute in different extract fractions due to their polarity. As ethyl acetate and n-butanol fractions of GT extract alleviated CCl₄-induced liver injury, we might be able to propose that the hepatoprotective chemicals of GT extract are dissolved in these fractions. The exact chemical(s) responsible for the hepatoprotective properties of GT and the mechanism(s) of hepatoprotection deserves more investigations. The proposed mechanism and the known chemical composition of GT, which might be responsible for its hepatoprotective properties, are summarized in figure 4.

Acknowledgments

The authors thank Pharmaceutical Sciences Research Center of Shiraz University of Medical Sciences for providing instrumental facilities to carry out this investigation.

Conflict of Interest

None declared.

6. Heidari R, Babaei H, Eghbal MA. Cytoprotective effects of taurine against toxicity induced by isoniazid and hydrazine in isolated rat hepatocytes. *Arch Indust Hyg Toxicol*. 2013;64:201-10.
7. Heidari R, Babaei H, Eghbal MA. Amodiaquine-induced toxicity in isolated rat hepatocytes and the cytoprotective effects of taurine and/or N-acetyl cysteine. *Res Pharm Sci*. 2014;9:97-105.
8. Sharma V, Singh M. Attenuation of N-nitrosodimethylamine induced hepatotoxicity by *Operculina turpethum* in Swiss Albino mice. *Iran J Basic Med Sci*. 2014;17:73-80.
9. Weber LWD, Boll M, Stampfl A. Hepatotoxicity and mechanism of action of haloalkanes: carbon tetrachloride as a toxicological model. *Crit Rev Toxicol*. 2003;33:105-36.
10. Tong J, Yao X, Zeng H, Zhou G, Chen Y, Ma B, Wang Y. Hepatoprotective activity of flavonoids from *Cichorium glandulosum* seeds *in vitro* and *in vivo* carbon tetrachloride-induced hepatotoxicity. *J Ethnopharmacol*. 2015;174:355-63.

11. Farida T, Salawu OA, Tijani AY, Ejiofor JI. Pharmacological evaluation of *Ipomoea asarifolia* (Desr.) against carbon tetrachloride-induced hepatotoxicity in rats. *J Ethnopharmacol.* 2012;142:642-6.
12. Niranjana Murthy H, Dandin VS, Yoeup Paek K. Hepatoprotective activity of ginsenosides from *Panax ginseng* adventitious roots against carbon tetrachloride treated hepatic injury in rats. *J Ethnopharmacol.* 2014;158:442-6.
13. Jadon A, Bhadauria M, Shukla S. Protective effect of *Terminalia belerica* Roxb. and gallic acid against carbon tetrachloride induced damage in albino rats. *J Ethnopharmacol.* 2007;109:214-8.
14. Mosaddegh M, Naghibi F, Moazzeni H, Pirani A, Esmaeili S. Ethnobotanical survey of herbal remedies traditionally used in Kohghiluyeh va Boyer Ahmad province of Iran. *J Ethnopharmacol.* 2012;141:80-95.
15. Hajimahmoodi M, Shams-Ardakani M, Saniee P, Siavoshi F, Mehrabani M, Hosseinzadeh H, Foroumadi P, Safavi M, Khanavi M, Akbarzadeh T, others. *In vitro* antibacterial activity of some Iranian medicinal plant extracts against *Helicobacter pylori*. *Nat Prod Res.* 2011;25:1059-66.
16. Ghasemi PA, Momeni M, Bahmani M. Ethnobotanical study of medicinal plants used by Kurd tribe in Dehloran and Abdanan districts, Ilam province, Iran. *Afr J Trad Compl Alt Med.* 2013;10:368-85.
17. Jamshidzadeh A, Fereidooni F, Salehi Z, Niknahad H. Hepatoprotective activity of *Gundelia tourenfortii*. *J Ethnopharmacol.* 2005;101:233-7.
18. Janbaz KH, Saeed SA, Gilani AH. Protective effect of rutin on paracetamol-and CCl₄-induced hepatotoxicity in rodents. *Fitoterapia.* 2002;73:557-63.
19. Mourelle M, Muriel P, Favari L, Franco T. Prevention of ccl4-induced liver cirrhosis by silymarin. *Fundament Clin Pharmacol.* 1989;3:183-91.
20. Kim S-H, Cheon HJ, Yun N, Oh S-T, Shin E, Shim KS, Lee S-M. Protective effect of a mixture of *Aloe vera* and *Silybum marianum* against carbon tetrachloride-induced acute hepatotoxicity and liver fibrosis. *J Pharmacol Sci.* 2009;109:119-27.
21. Heidari R, Jamshidzadeh A, Keshavarz N, Azarpira N. Mitigation of Methimazole-Induced Hepatic Injury by Taurine in Mice. *Sci Pharm.* 2014;83:143-58.
22. Jamshidzadeh A, Heidari R, Razmjou M, Kari-mi F, Moein MR, Farshad O, Akbarizadeh AR, Shayesteh MRH. An *in vivo* and *in vitro* investigation on hepatoprotective effects of *Pimpinella anisum* seed essential oil and extracts against carbon tetrachloride-induced toxicity. *Iran J Bas Med Sci.* 2015;18:205-11.
23. Heidari R, Niknahad H, Jamshidzadeh A, Azarpira N, Bazyari M, Najibi A. Carbonyl Traps as Potential Protective Agents against Methimazole-Induced Liver Injury. *J Biochem Mol Toxicol.* 2015;29:173-81.
24. Moezi L, Heidari R, Amirghofran Z, Nekooeian AA, Monabati A, Dehpour AR. Enhanced anti-ulcer effect of pioglitazone on gastric ulcers in cirrhotic rats: The role of nitric oxide and IL-1b. *Pharmacol Rep.* 2013;65:134-43.
25. Sedlak J, Lindsay RH. Estimation of total, protein-bound, and nonprotein sulfhydryl groups in tissue with Ellman's reagent. *Anal Biochem.* 1968;25:192-205.
26. Heidari R, Taheri V, Rahimi HR, Shirazi Yeganeh B, Niknahad H, Najibi A. Sulfasalazine-induced renal injury in rats and the protective role of thiol-reductants. *Renal failure.* 2015;1-5.
27. Heidari R, Babaei H, Roshangar L, Eghbal MA. Effects of enzyme induction and/or glutathione depletion on methimazole-induced hepatotoxicity in mice and the protective role of N-acetylcysteine. *Advanc Pharm Bull.* 2014;4:21-8.
28. Heidari R, Jamshidzadeh A, Keshavarz N, Azarpira N. Mitigation of Methimazole-Induced Hepatic Injury by Taurine in Mice. *Sci Pharm.* 2015;83:143-58.
29. Uchiyama M, Mihara M. Determination of malonaldehyde precursor in tissues by thiobarbituric acid test. *Anal Biochem.* 1978;86:271-8.
30. Gaudio E, Onori P, Franchitto A, Sferra R, Riggio O. Liver metabolic zonation and hepatic microcirculation in carbon tetrachloride-induced experimental cirrhosis. *Digest Dis Sci.* 1997;42:167-77.
31. Ritter C, Reinke A, Andrades M, Martins MR, Rocha J, Menna-Barreto S, Quevedo J, Moreira JCF, Dal-Pizzol F. Protective effect of N-acetylcysteine and deferoxamine on carbon tetrachloride-induced acute hepatic failure in rats. *Crit Care Med.* 2004;32:2079-83.
32. Vargas-Mendoza N, Madrigal-Santillán E, Morales-González A, Esquivel-Soto J, Esquivel-Chirino C, García-Luna Y González-Rubio M, Gayosso-de-Lucio JA, Morales-González JA.

Hepatoprotective effect of silymarin. *World J Hepatol*. 2014;6:144-9.

33. Czaja MJ, Xu J, Alt E. Prevention of carbon tetrachloride-induced rat liver injury by soluble tumor necrosis factor receptor. *Gastroenterology*. 1995;108:1849-54.
34. Weber LWD, Boll M, Stampfl A. Hepatotoxicity and mechanism of action of haloalkanes: carbon tetrachloride as a toxicological model. *CRC Crit Rev Toxicol*. 2003;33:105-36.
35. Sabahi M, Ramezani M, Jaffari G, Heravi G, Bahaeddini F, Aynehchi Y. Survey of Iranian plants for saponins, alkaloids, flavonoids, and tannins. IV. The plants of Kerman Province. *Pharm Biol*. 1985;23:165-75.
36. Halabi S, Battah AA, Aburjai T, Hudaib M. Phytochemical and Antiplatelet Investigation of *Gundelia tournefortii*. *Pharm Biol*. 2005;43:496-500.
37. Haghi G, Hatami A, Arshi R. Distribution of caffeic acid derivatives in *Gundelia tournefortii* L. *Food Chem*. 2011;124:1029-35.
38. Haghi G, Hatami A. Simultaneous quantification of flavonoids and phenolic acids in plant materials by a newly developed isocratic high-performance liquid chromatography approach. *J Agr Food Chem*. 2010;58:10812-6.
39. Adzet T, Camarasa J, Laguna JC. Hepatoprotective activity of polyphenolic compounds from *Cynara scolymus* against CCl₄ toxicity in isolated rat hepatocytes. *J Nat Prod*. 1987;50:612-7.
40. Wang M, Simon JE, Aviles IF, He K, Zheng Q-Y, Tadmor Y. Analysis of antioxidative phenolic compounds in artichoke (*Cynara scolymus* L.). *J Agricult Food Chem*. 2003;51:601-8.
41. Tirkey N, Pikhwal S, Kuhad A, Chopra K. Hesperidin, a citrus bioflavonoid, decreases the oxidative stress produced by carbon tetrachloride in rat liver and kidney. *BMC Pharmacol*. 2005;5:1-8.
42. Tipoe GL, Leung TM, Liong EC, Lau TYH, Fung ML, Nanji AA. Epigallocatechin-3-gallate (EGCG) reduces liver inflammation, oxidative stress and fibrosis in carbon tetrachloride (CCl₄)-induced liver injury in mice. *Toxicology*. 2010;273:45-52.
43. Kapil A, Koul IB, Suri OP. Antihepatotoxic Effects of chlorogenic acid from *Anthocephalus cadamba*. *Phytother Res*. 1995;9:189-93.
44. Lee KJ, Choi JH, Khanal T, Hwang YP, Chung YC, Jeong HG. Protective effect of caffeic acid phenethyl ester against carbon tetrachloride-induced hepatotoxicity in mice. *Toxicology*. 2008;248:18-24.
45. Pavanato A, Tuñón MJ, Sánchez-Campos S, Marroni CA, Llesuy S, González-Gallego J, Marroni N. Effects of quercetin on liver damage in rats with carbon tetrachloride-induced cirrhosis. *Dig Dis Sci*. 2003;48:824-9.
46. Cui Y, Han Y, Yang X, Sun Y, Zhao Y. Protective effects of quercetin and quercetin-5',8-disulfonate against carbon tetrachloride-caused oxidative liver injury in mice. *Molecules*. 2013;19:291-305.
47. Jadon A, Bhadauria M, Shukla S. Protective effect of *Terminalia bellerica* Roxb. and gallic acid against carbon tetrachloride induced damage in albino rats. *J Ethnopharmacol*. 2007;109:214-8.
48. Tung Y-T, Wu J-H, Huang C-C, Peng H-C, Chen Y-L, Yang S-C, Chang S-T. Protective effect of *Acacia confusa* bark extract and its active compound gallic acid against carbon tetrachloride-induced chronic liver injury in rats. *Food Chem Toxicol*. 2009;47:1385-92.
49. Halliwell B, Chirico S. Lipid peroxidation: its mechanism, measurement, and significance. *American J Clin Nut*. 1993;57:715-24.
50. Forman HJ, Zhang H, Rinna A. Glutathione: Overview of its protective roles, measurement, and biosynthesis. *Mol Asp Med*. 2009;30:1-12.
51. Bhadauria M, Nirala SK, Shukla S. Propolis protects CYP 2E1 enzymatic activity and oxidative stress induced by carbon tetrachloride. *Mol Cell Biochem*. 2007;302:215-24.

