

## Intracranial hemorrhage after carotid artery stenting in two patients taking omega-3 fatty acids with dual antiplatelet therapy: two case reports

Afshin Borhani-Haghighi<sup>1,2</sup>, Farzaneh Foroughinia<sup>1,3,\*</sup>, Elaheh Jamshidi<sup>1,4</sup>, Haniyeh Javanmardi<sup>1,4</sup>

<sup>1</sup>Clinical Neurology Research Center, Shiraz University of Medical Sciences, Shiraz, Iran.

<sup>2</sup>Department of Neurology, School of Medicine, Shiraz University of Medical Sciences, Shiraz, Iran.

<sup>3</sup>Department of Clinical Pharmacy, School of Pharmacy, Shiraz University of Medical Sciences, Shiraz, Iran

<sup>4</sup>Student Research Committee, Shiraz University of Medical Sciences, Shiraz, Iran.

### Abstract

Patients undergoing Carotid Artery Stenting (CAS) may encounter serious complications including Intracranial hemorrhage (ICH). ICH after carotid re-vascularization has been usually attributed to cerebral hyperperfusion syndrome (CHS) and it is reported as a significant cause of mortality and morbidity. Factors mentioned as risk factors for ICH after carotid intervention are preoperative hypertension, renal failure, bilateral carotid disease or contralateral carotid occlusion, impaired cerebrovascular reserve, female gender, age, nonselective admission, and increased Charlson comorbidities score. In this study, we report two cases of ICH after CAS in patients receiving dual antiplatelet regimen plus omega-3 fatty acids before and after carotid intervention. It seems that administration of omega-3 with other antiplatelets could augment inhibition of platelet aggregation and may increase the risk of ICH in patients undergoing CAS especially in those with several risk factors for ICH. These findings are important because of the wide availability of omega-3 supplements as an over-the-counter (OTC) drug and the propensity for usage of it in alternative medicine.

**Keywords:** Carotid artery stenting, Dual antiplatelets, Fatty Acids, Intracranial Hemorrhage, Omega-3.

### 1. Introduction

Carotid stenosis is an important cause of ischemic stroke or transient ischemic attack (TIA) and accounts for 20 to 25% of all cases of stroke. Carotid revascularization is an interventional treatment for both symptomatic and asymptomatic patients with severe carotid artery stenosis as a preventive strategy against stroke recurrence. Carotid Artery Stenting (CAS) and carotid endarterectomy (CEA) are currently being used for carotid intervention (1). Focal cerebral ischemia and hemorrhagic events are major complica-

tions of these interventions that limit the benefit of these procedures in overall stroke prevention. The risk of stroke or death related to carotid revascularization estimated to be about 2.3%-5.8%. A study on CAS-treated patients reported a risk of stroke of 9.5% within 30 days of intervention (2, 3). It is assumed that about 23% of all post-procedural strokes are hemorrhagic. A consistently reported association between hypertension and an increased risk of ICH (Intracranial hemorrhage) and CHS (Cerebral hyperperfusion syndrome) after carotid interventions were noted. Therefore, it is suggested that aggressive treatment of hypertension in patients at high risk for ICH could result in a lower incidence of CHS and ICH after CAS (4).

*Corresponding Author:* Farzaneh Foroughinia, Department of Clinical Pharmacy, School of Pharmacy, Shiraz University of Medical Sciences, Shiraz, Iran  
Email: farzanehforoughinia@yahoo.com

Reduction or prevention of postoperative complications will be required to improve the safety and efficacy of carotid procedures. For this purpose, one of routinely used recommendations is administration of combined antiplatelet therapy with aspirin and clopidogrel before CAS and for one month afterwards (5).

In this study, we reported two cases of ICH pretreated with dual antiplatelet drugs (aspirin and clopidogrel) plus omega-3 before CAS. Omega-3 was used for these patients as an add-on therapy for further inhibition of platelet aggregation. According to studies, it is assumed that omega-3 could be an effective drug for the reduction of the risk of major adverse cardiac events (MACE) in patients undergoing percutaneous coronary intervention (PCI). In contrast to the reported beneficial effect of omega-3 in patients undergoing coronary stenting (6), two cases of hemorrhagic infarction were seen after the addition of omega-3 supplement to the dual antiplatelet regimen before CAS in our study.

## 2. Case reports

### 2.1. Case 1

An 82-year-old normotensive male presented to the neurologist in September 2017 with acute onset of left-sided headache, neck pain, urinary frequency, left facial weakness and left hemiparesis that began abruptly following a forceful cough. On admission, the patient was afebrile but confused and dysphasic. He had been in good health before onset of these symptoms. His medical history was significant for a previous CVA three months prior to admission. He had a history of hyperlipidemia, renal failure (estimated GFR = 36 cc/min) TIA and myocardial infarction, but reported no history of previous seizure, migraine and loss of consciousness. His Glasgow Coma Scale was 14 at the time of admission. No other conventional risk factors such as diabetes, hypertension

and smoking were found. On examination, his blood pressure was 140/70 mm Hg. His laboratory tests are summarized in Table 1. Other routine tests including, CBC and platelet counts, blood sugar, urinalysis, coagulation studies, renal and thyroid function were all normal. He had been treated with antiplatelet drugs (aspirin 80 mg/d and 75 mg/d clopidogrel), atorvastatin, losartan and amlodipine in a private hospital and subsequently referred to our stroke unit. Muscle stretch reflexes were brisk and Babinski sign was negative. Color Doppler sonography was performed and revealed the presence of a large calcified plaque in the proximal portion of internal carotid artery (ICA) in the right side that causes a severe stenosis (more than 70%) of the lumen, showed contralateral carotid occlusion in this case .

Carotid angioplasty plus stenting was applied for his treatment. Therefore, the patient was pretreated with clopidogrel, aspirin and omega-3 (aspirin 80 mg/day after a loading dose of 325 mg, and clopidogrel 75 mg/day after a loading dose of 600 mg at least 48 hours before the CAS plus 3000 mg loading dose of omega-3 fatty acids 12 hours before the procedure and 1000 mg the day after the procedure) to reduce the risk of reinfarction. The procedure was well tolerated by the patient without significant complications.

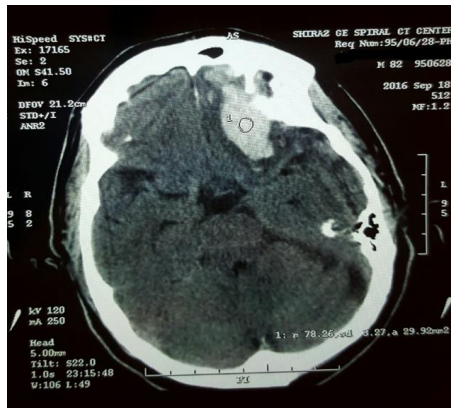Carotid stenting was well tolerated by the patient and postoperative angiogram showed a 30% residual stenosis. The post-operative blood pressure was reported to be 160/90 mmHg. The patient remained well until 8 hours after the procedure, when he developed neurological symptoms such as headache and aggravation of right-side weakness and urinary incontinence.

CT (computed tomography) scan demonstrated a rim of hemorrhagic transformation at the periphery of old stroke lesion in the left frontoparietal lobe that was associated with peripheral edema (figure 1) (5).

**Table 1.** Laboratory findings of two cases.

lab. values	BUN	serum creatinine	Hgb	Plt
case 1	20(mg/dl)	1.4(mg/dl)	13.7(g/dL)	155(1000/ $\mu$ L)
case 2	23(mg/dl)	1.4 (mg/dl)	15(g/dL)	198(1000/ $\mu$ L)

BUN: Blood Urea Test, HGB: Hemoglobin, PLT: Platelet.



**Figure 1.** Brain computerized tomography (CT) Scan revealed a hemorrhage in the left frontoparietal lobe.

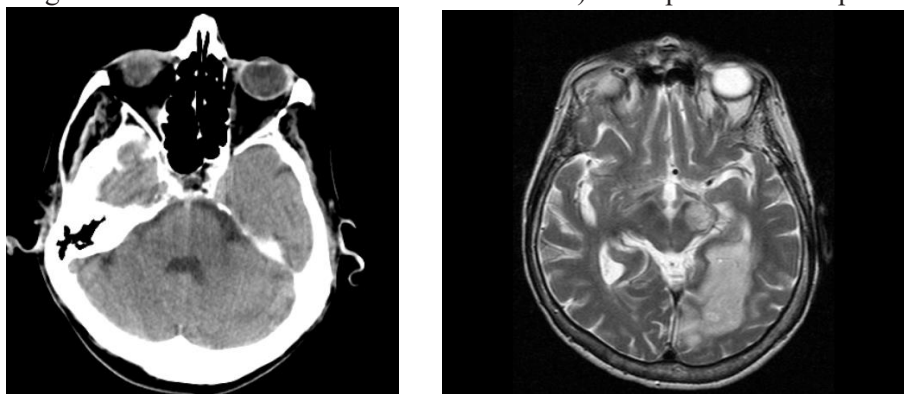
All antiplatelet drugs and omega-3 were stopped and conservative treatment (general and respiratory and cardiovascular supportive care) was advised. The patient improved in a few days and clopidogrel, and aspirin was restarted after 5 and 7 days, respectively. At one-month follow-up, he had total recovery of left hemiparesis, normal language function and no evidence of stroke, MI and TIA.

## 2.2. Case 2

A 73-year-old, female patient admitted to our hospital with a chief complaint of sudden onset right sided weakness and paresthesia and right homonymous hemianopia. She had a medical history of smoking, hypertension, hyperlipidemia, diabetes mellitus type 2, renal failure (estimated GFR = 40 cc/min), previous CVA and previous Coronary Artery Bypass Graft (CABG) surgery. Neurological examination on admission revealed disturbance of consciousness and neck stiffness. Her initial Glasgow Coma Scale was 14. Hema-

tological and biochemical laboratory data are disclosed in table 1. At the time of examination, she had been treated with antiplatelet drugs (aspirin 80 mg/d and 75 mg/d clopidogrel), atorvastatin, losartan and metformin for several years. The first color Doppler sonography and cerebral vessels angiography showed a 70% stenosis of proximal part of right internal carotid artery with a severe luminal narrowing. The patient had to be treated with carotid angioplasty plus stenting in view of her deteriorating neurological status. Before the stent placement procedure, she was pretreated with clopidogrel, aspirin and omega-3 (aspirin 80 mg/day after a loading dose of 325 mg, and clopidogrel 75 mg/day after a loading dose of 600 mg at least 48 hours before the CAS plus 3000 mg loading dose of omega-3 fatty acids 12 hours before the procedure and 1000 mg the day after the procedure) for reduction of periprocedural infarction.

She tolerated the procedure well, and the right ICA stenosis was resolved (residual stenosis <20%). Postoperative blood pressure was not more



**Figure 2.** Brain computerized tomography (CT) Scan revealed a hemorrhage in bilateral occipital areas.

than 166/90 mmHg. Intravenous nitroglycerin was infused until the blood pressure was stabilized.

Twelve hours after the procedure, the patient developed convulsion, severe delusions, impaired state of consciousness, and urinary incontinence. The symptomatology and CT findings were attributed to the hemorrhagic infarction. Brain CT showed gyral hemorrhage in bilateral occipital areas (Figure 2) (5). Therefore, all antiplatelet drugs and omega-3 were stopped and conservative treatment (general and respiratory and cardiovascular supportive care) was advised. The patient improved in a few days and clopidogrel, and aspirin was restarted after 5 and 7 days, respectively.

### 3. Discussion

ICH after carotid re-vascularization has been usually attributed to cerebral hyperperfusion syndrome (CHS) and it is reported as a significant cause of mortality and morbidity. It is presumed that acute ICH (within 12 hours) following CAS, result in partially disability in up to 30% and mortality in 50% of patients (7).

Preoperative hypertension, renal failure, bilateral carotid disease or contralateral carotid occlusion, impaired cerebrovascular reserve, female gender, age, nonselective admission, increased Charlson comorbidities score as well as undergoing CAS procedure were mentioned as risk factors that predisposed patients to ICH after carotid intervention (7, 8).

In our report, both cases have several risk factors for ICH including medical history of renal failure, pre- and post-operative hypertension, older age and doing CAS procedure. Also, case 1 has contralateral carotid occlusion and case 2 has female gender as other risk factor for post-CAS ICH. As mentioned in previous studies, these factors in-

### 4. References

1. Mukherjee D, Patil CG. Epidemiology and the global burden of stroke. *World Neurosurg.* 2011 Dec;76:S85-90. doi: 10.1016/j.wneu.2011.07.023.
2. Gahremanpour A, Perin EC, Silva G. Carotid artery stenting versus endarterectomy: a systematic review. *Tex Heart Inst J.* 2012;39:474-87.
3. Jim J, Rubin BG, Ricotta JJ, Kenwood CT, Siami FS, Sicard GA, et al. Society for Vascular

increased the risk of ICH after carotid intervention.

Some studies reported dual antiplatelet therapy (aspirin and clopidogrel) plus omega-3 as a preventive approach for the reduction of MACE during and after the coronary stent placement (6); however, its effect in the setting of carotid stenting is not studied. Antiplatelet effect of omega-3 and its benefit in augmentation of the antiplatelet effect of aspirin and clopidogrel combination were mainly reported for this positive role of omega 3 in patients following PCI (6). Few data exist on whether or not fish oil can be used safely with other antiplatelet or anticoagulant drugs.

To the best of our knowledge and available databases, this study is the first report of hemorrhagic infarction associated with omega-3 supplementation with routine dual antiplatelet therapy in patients tolerating CAS. Drug interaction probability scale was estimated to be 2 for these patients, therefore; the reported interaction is possible for our cases.

According to the reported ICH in these two cases, it seems that co-administration of omega-3 with other antiplatelets could augment inhibition of platelet aggregation and may increase the risk of ICH in patients undergoing CAS especially in those with several risk factors for post-CAS ICH. These findings are important because of the wide availability of omega-3 supplements as an over-the-counter (OTC) drug and the propensity for usage of it in alternative medicine in patients with cardiovascular or cerebrovascular diseases who are already taking antiplatelet medicines and are candidate for CAS.

### Conflict of Interest

None declared.

Surgery (SVS) Vascular Registry evaluation of comparative effectiveness of carotid revascularization procedures stratified by Medicare age. *J Vasc Surg.* 2012;55:1313-20; discussion 1321. doi: 10.1016/j.jvs.2011.11.128.

4. Abou-Chebl A, Yadav JS, Reginelli JP, Bajzer C, Bhatt D, Krieger DW. Intracranial hemorrhage and hyperperfusion syndrome following carotid artery stenting: risk factors, prevention,

and treatment. *J Am Coll Cardiol*. 2004 May 5;43:1596-601.

5. Foroughinia F, Jamshidi E, Javanmardi H, Safari A, Borhani-Haghighi A. Effectiveness and safety of omega-3 fatty acids for the prevention of ischemic complications following carotid artery stenting: An early terminated pilot study. *Iran J Neurol*. 2018 Jan 5;17(1):11-17.

6. Foroughinia F, Salamzadeh J, Namazi MH. Protection from procedural myocardial injury by omega-3 polyunsaturated fatty acids (PUFAs): is related with lower levels of creatine kinase-MB (CK-MB) and troponin I? *Cardiovasc Ther*. 2013

Oct;31(5):268-73. doi: 10.1111/1755-5922.12016.

7. Galyfos G, Sianou A, Filis K. Cerebral hyperperfusion syndrome and intracranial hemorrhage after carotid endarterectomy or carotid stenting: A meta-analysis. *J Neurol Sci*. 2017 Oct 15;381:74-82. doi: 10.1016/j.jns.2017.08.020. Epub 2017 Aug 18.

8. Timaran CH, Veith FJ, Rosero EB, Modrall JG, Valentine RJ, Clagett GP. Intracranial hemorrhage after carotid endarterectomy and carotid stenting in the United States in 2005. *J Vasc Surg*. 2009 Mar;49(3):623-8; discussion 628-9. doi: 10.1016/j.jvs.2008.09.064.

