

Central Serous Chorioretinopathy Following Use of Desmopressin Nasal Spray: A Case Report

Vahid Beigi^{1,*}, Mehrnoosh Maalagh¹, Mohammad sadegh Beigi¹

¹Poostchi Ophthalmology Research Center, Department of Ophthalmology, School of Medicine, Shiraz University of Medical Sciences, Shiraz, Iran.

Abstract

In the present report, we describe a middle-aged man who experienced decreased visual acuity and metamorphopsia several times following the administration of desmopressin nasal spray. Ophthalmologic examination revealed visual acuity of OD: 4/10 and OS: 9/10 with correction. Pigmentary change and retinal elevation was present in fundus examination. Finding was documented with optical coherence tomography (OCT) and Fluorescein angiography (FA). The patient was diagnosed with central serous chorioretinopathy (CSCR) due to consumption of desmopressin nasal spray. We conclude that desmopressin might lead to CSCR but more study is recommended to confirm this hypothesis.

Keywords: CSCR, Desmopressin, Central Serous Chorioretinopathy.

1. Introduction

Desmopressin is prescribed to control excessive thirst, diabetes insipidus (DI), large amount of urine due to head injury and also bleeding tendency disorders like haemophilia and von-willebrand disease.

Some general side effects of this medication can be seizure, irritability, weight gain, hallucination, and drowsiness.

Regarding its ocular side effects, Kisma et al. reported 2 cases of middle-aged men with central serous chorioretinopathy and also 2 cases of decreased visual acuity were reported by UK health and care agency following desmopressin use(1).

2. Case presentation

A 59-year-old man was referred to the ophthalmology clinic due to decreased visual acuity (VA) in his right eye (RE) from 2 weeks prior

to referral. The patient reported a two time history of blurred vision during the past 3 years. The best corrected visual acuity (BCVA) was 4/10 in RE and 9/10 in the left eye (LE). Relative afferent pupillary defect was negative in both eyes. Ocular motility was normal. Slit lamp examination of the anterior segment was normal in both eyes. Measurement of intraocular pressure (IOP) was done with air-puff tonometer and IOP was 13 mmHg in RE and 12 mmHg in LE. Fundus examination by indirect ophthalmoscope shows mild pigmentary change and elevation of retina in macula in RE (figure 1) and normal fundus examination in LE. OCT was requested and revealed neurosensory detachment in RE (figure 1). FA shows expansile dot pattern.

Patient was diagnosed with CSCR that could be caused by desmopressin nasal spray administered for the patient's DI since 7 years ago.

3. Discussion

The etiology of CSCR is unknown. Common associations reported include endogenous & exogenous hyper cortisolism, stress, "type A"

Corresponding Author: Vahid Beigi, Poostchi Ophthalmology Research Center, Department of Ophthalmology, School of Medicine, Shiraz University of Medical Sciences, Shiraz, Iran.
Email: v.beigi66@gmail.com

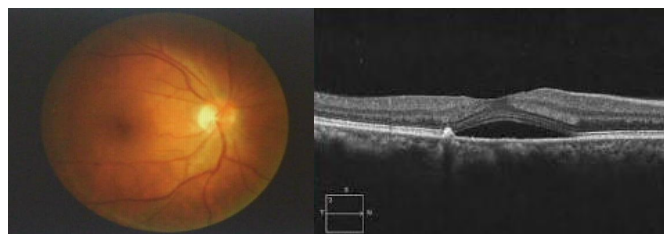


Figure 1. fundus photograph of the right eye (left),optical coherence tomography of the right eye (right).

personality, bone marrow and organ transplantation, systemic lupus erythematosus and pregnancy (2-9). Some rare associations having been reported include Goodpasture's syndrome and Weber-Christian disease (10, 11).

Considering desmopressin's role in inducing cortisol release (12), increase in levels of cortisol and ACTH can be accounted responsible for the CSCR and decreased visual acuity.

In our report, we have seen a rare case of desmopressin induced eye defect which was accompanied with reduced visual acuity, therefore

4. References

1. Kisma N, Loukianou E, Pal B. Central Serous Chorioretinopathy Associated with Desmopressin Nasal Spray: Causality or Unfortunate Association. *Case Rep Ophthalmol.* 2018;9:120-5.
2. Bouzas EA, Scott MH, Mastorakos G, Chrousos GP, Kaiser-Kupfer MI. Central serous chorioretinopathy in endogenous hypercortisolism. *Arch Ophthalmol.* 1993;111:1229-33.
3. Carnahan MC, Goldstein DA. Ocular complications of topical, peri-ocular, and systemic corticosteroids. *Curr Opin Ophthalmol.* 2000;11:478-83.
4. Chaine G, Haouat M, Menard-Molcard C, Favard C, Vignal-Clermont C, Campinchi-Tardy F, et al. [Central serous chorioretinopathy and systemic steroid therapy]. *J Fr Ophthalmol.* 2001;24:139-46.
5. Fawzi AA, Cunningham ET, Jr. Central serous chorioretinopathy after bone marrow transplantation. *Am J Ophthalmol.* 2001;131:804-5.
6. Abu el-Asrar AM. Central serous chorioretinopathy complicating systemic corticosteroid therapy. *Eur J Ophthalmol.* 1997;7:297-300.

we suggest further study for investigating the role of desmopressin as the main cause of CSCR.

Acknowledgement

We appreciate our coworker in the ophthalmology department of our clinic and also the patient that permitted us to use his data as a case report.

Conflict of Interest

None declared.

7. Chumbley LC, Frank RN. Central serous retinopathy and pregnancy. *Am J Ophthalmol.* 1974;77:158-60.
8. Gelber GS, Schatz H. Loss of vision due to central serous chorioretinopathy following psychological stress. *Am J Psychiatry.* 1987;144:46-50.
9. Williams RB, Jr., Lane JD, Kuhn CM, Melosh W, White AD, Schanberg SM. Type A behavior and elevated physiological and neuroendocrine responses to cognitive tasks. *Science (New York, NY).* 1982;218(4571):483-5.
10. Boucher MC, el Toukhy EA, Cormier G. Bilateral serous retinal detachments associated with Goodpasture's syndrome. *Can J Ophthalmol.* 1998;33:226-7.
11. Dinakaran S, Desai SP. Central serous retinopathy associated with Weber-Christian disease. *Eur J Ophthalmol.* 1999;9:139-41.
12. Malerbi DA, Mendonca BB, Liberman B, Toledo SP, Corradini MC, Cunha-Neto MB, et al. The desmopressin stimulation test in the differential diagnosis of Cushing's syndrome. *Clin Endocrinol (Oxf).* 1993;38:463-72.